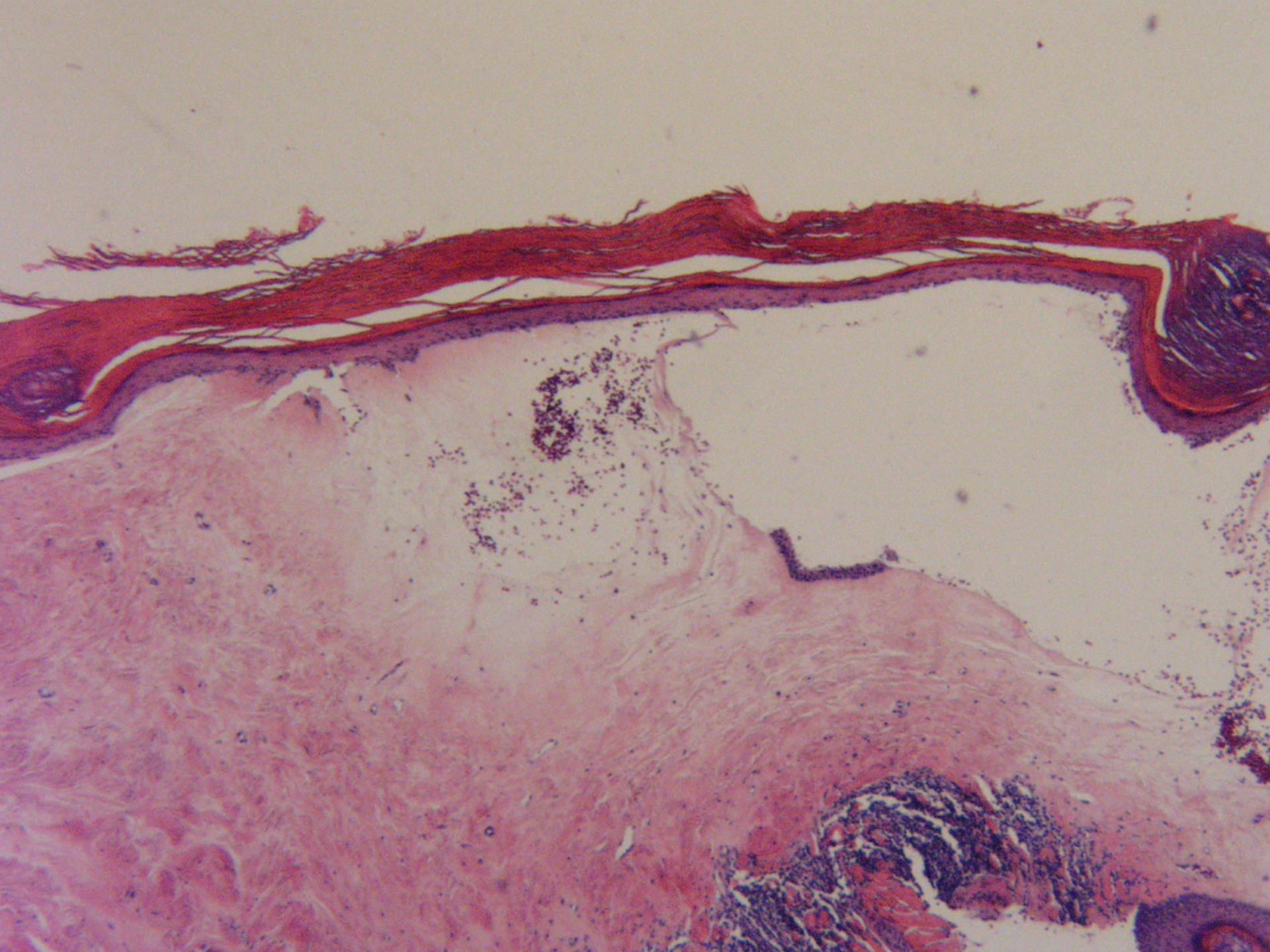
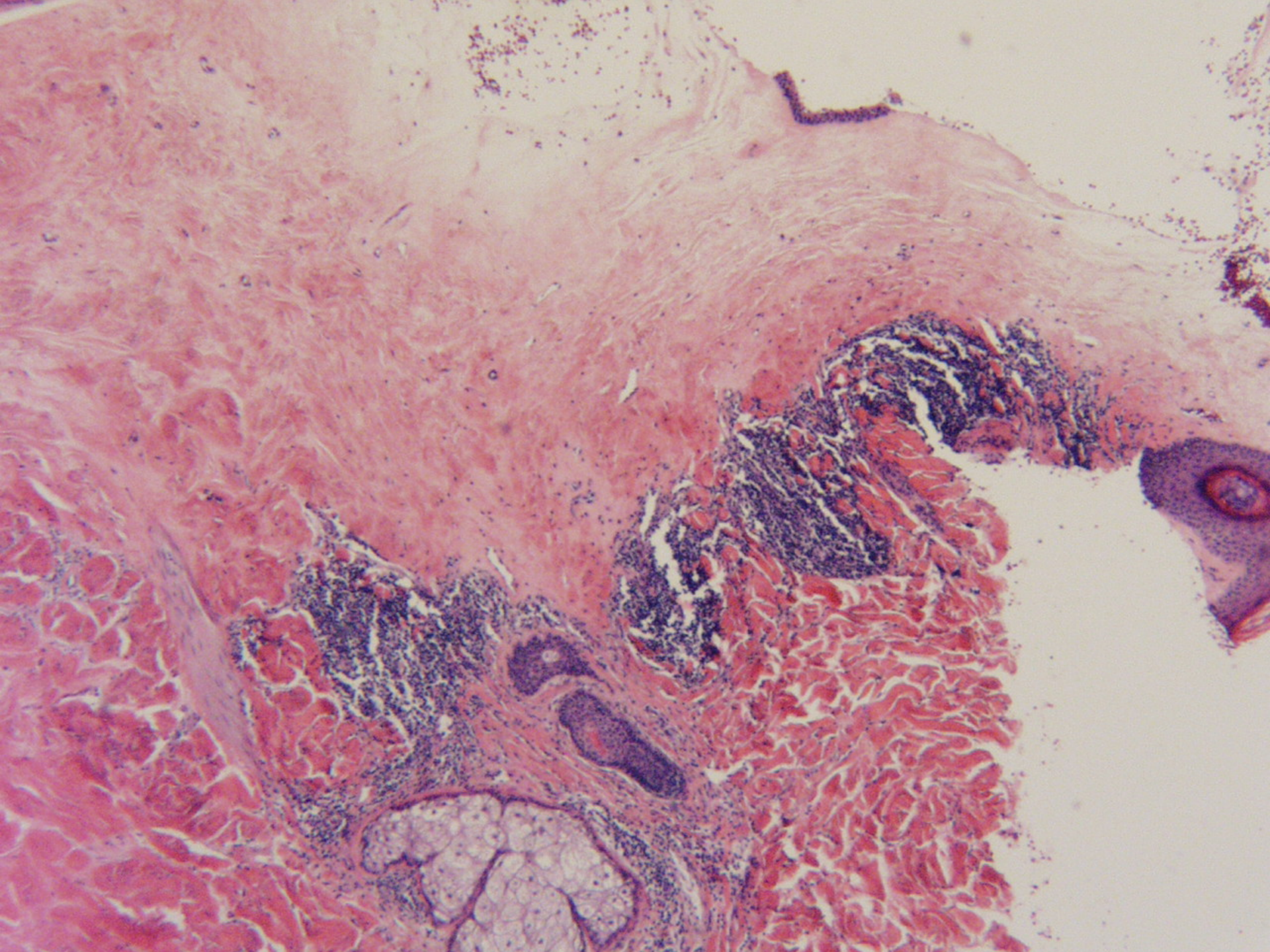


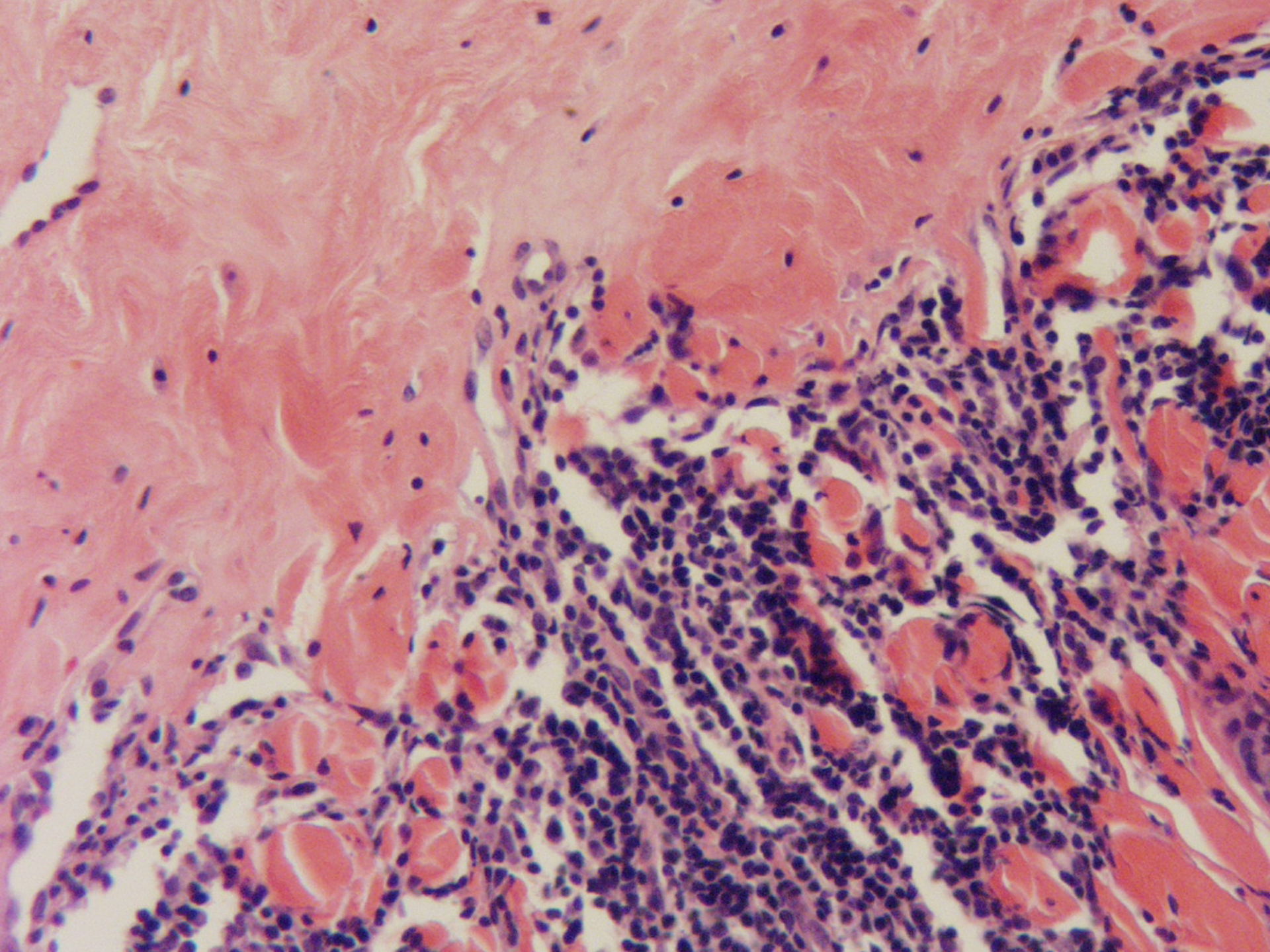
Dermatopathology Slide Review Part 9

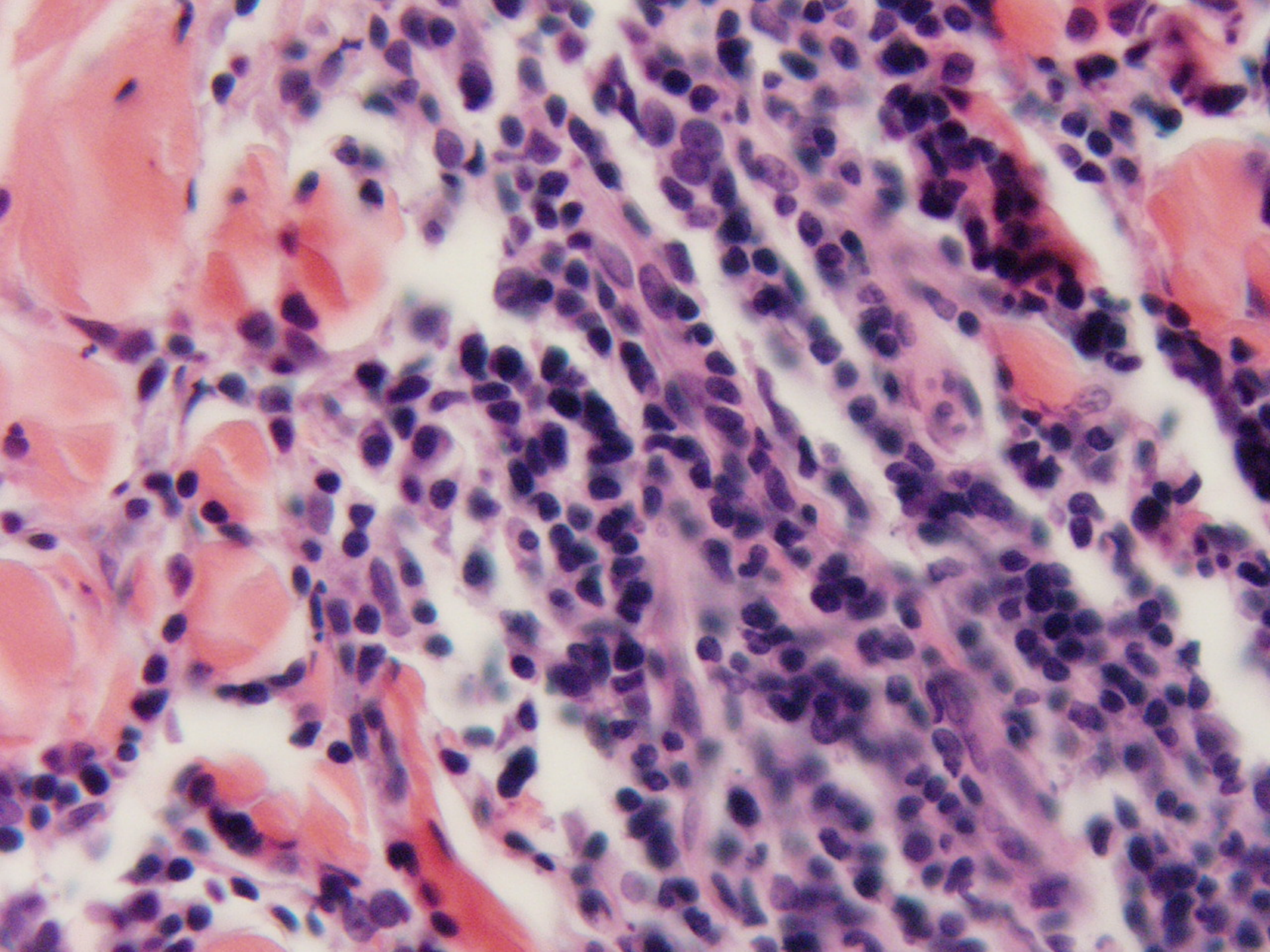
Paul K. Shitabata, M.D.

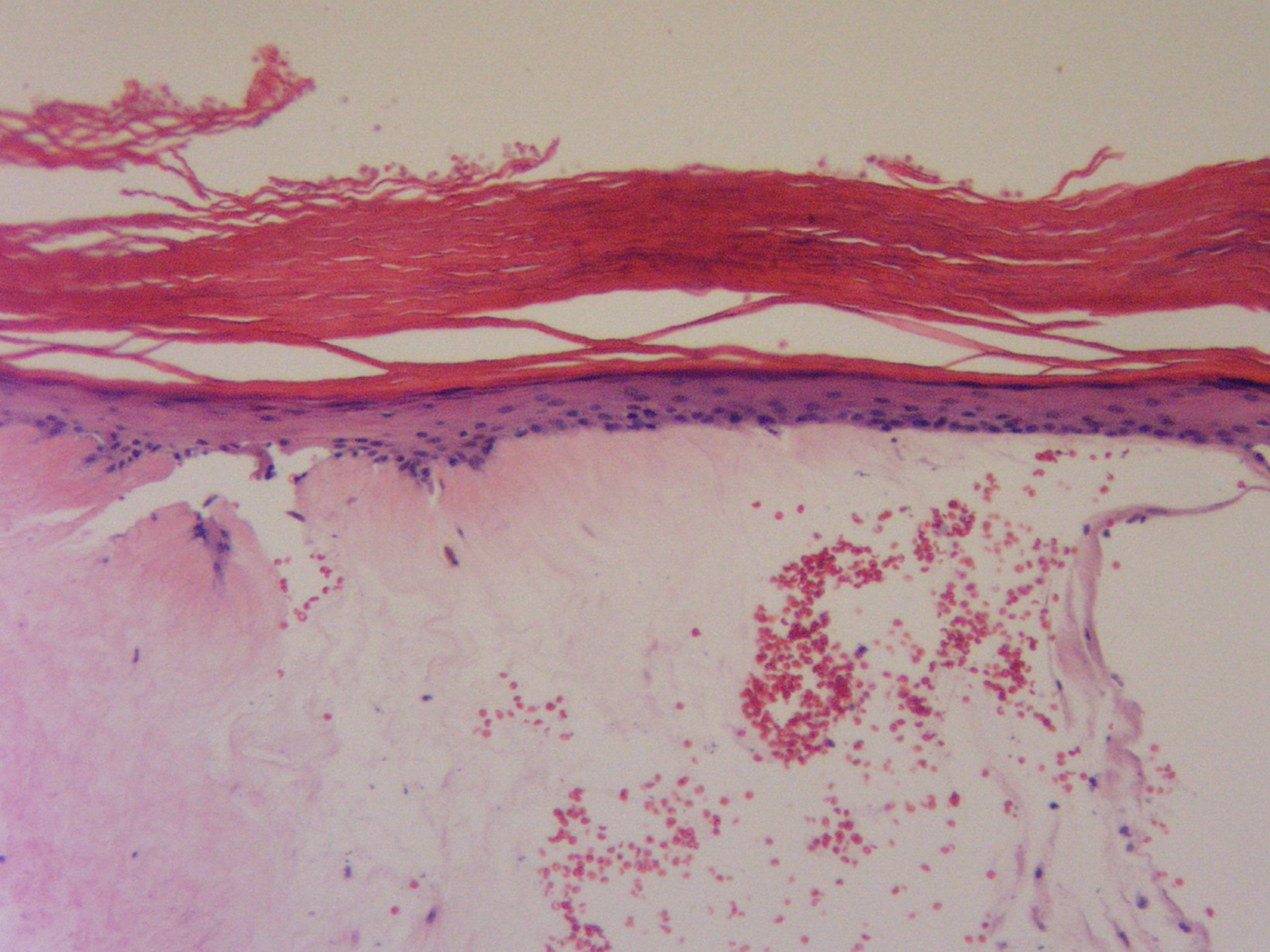
Dermatopathology Institute

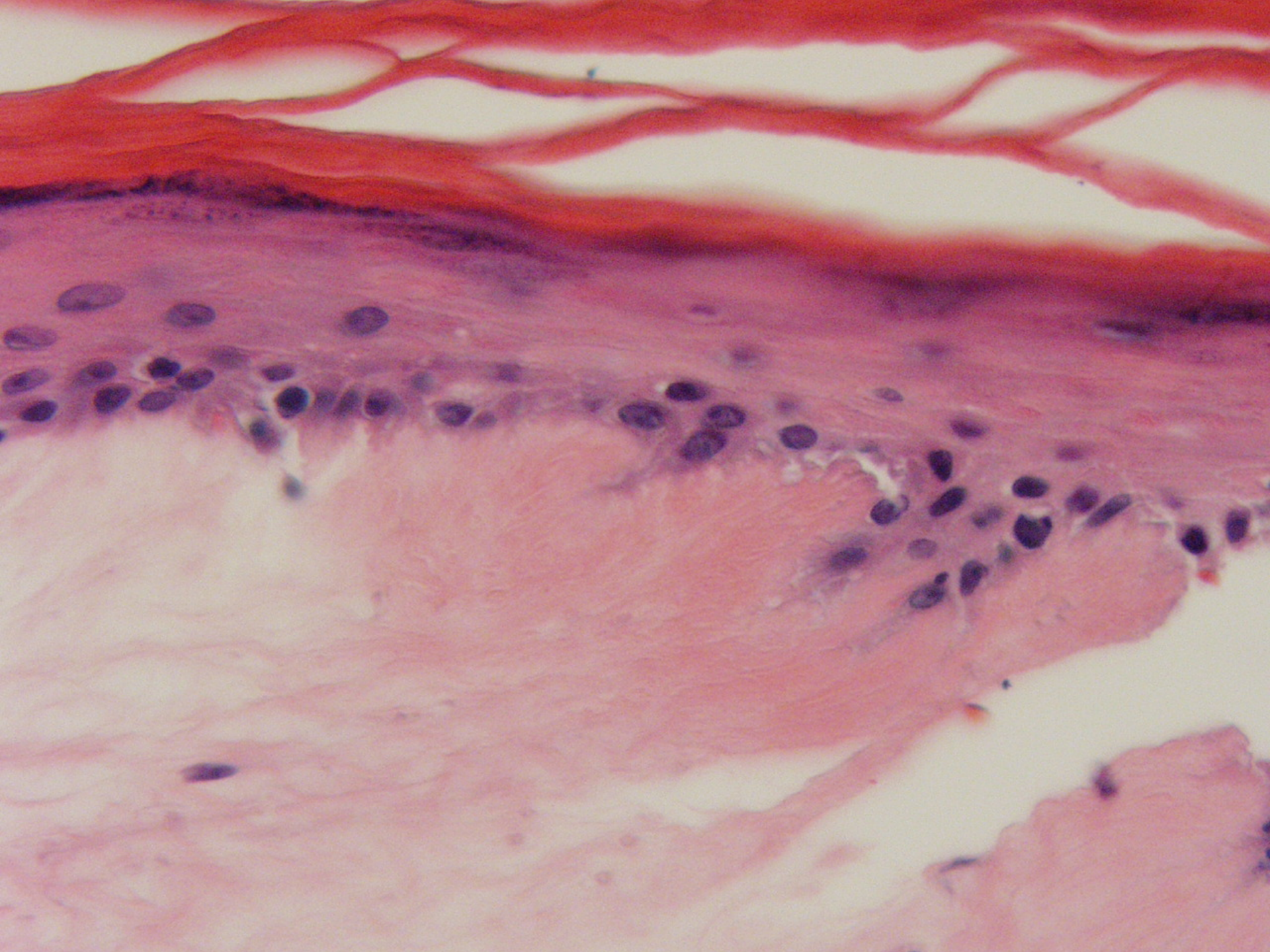








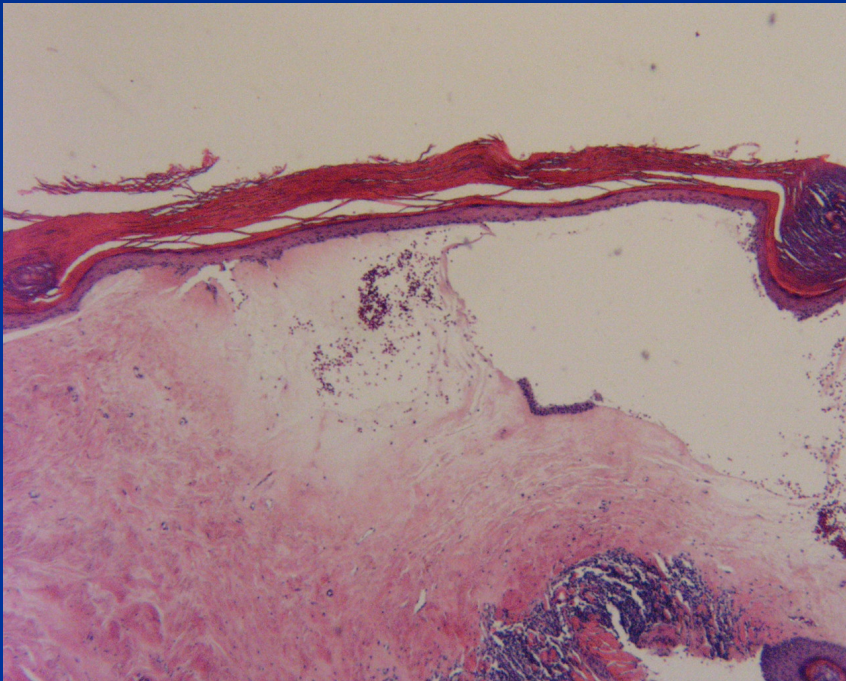




What is your differential diagnosis and what special stains/IHC would be helpful?

Lichen Sclerosus

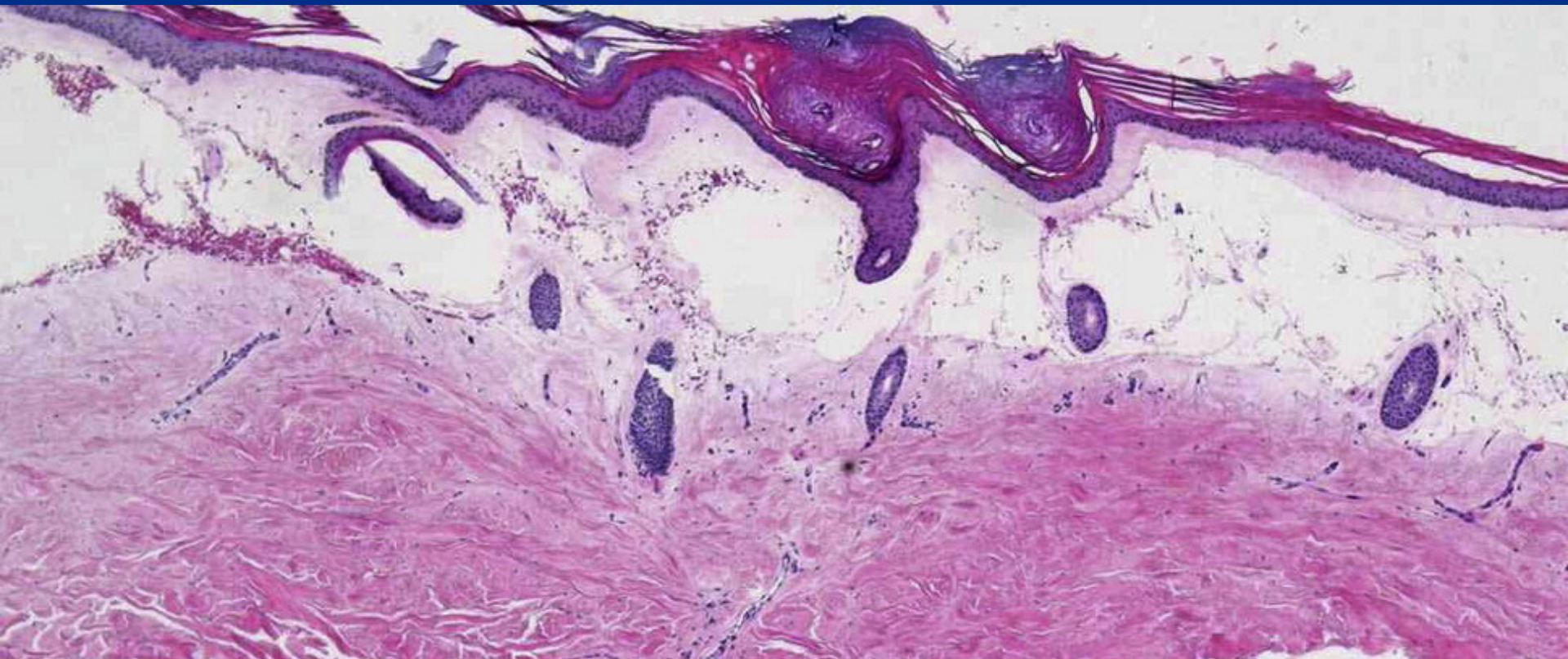
Histopathology



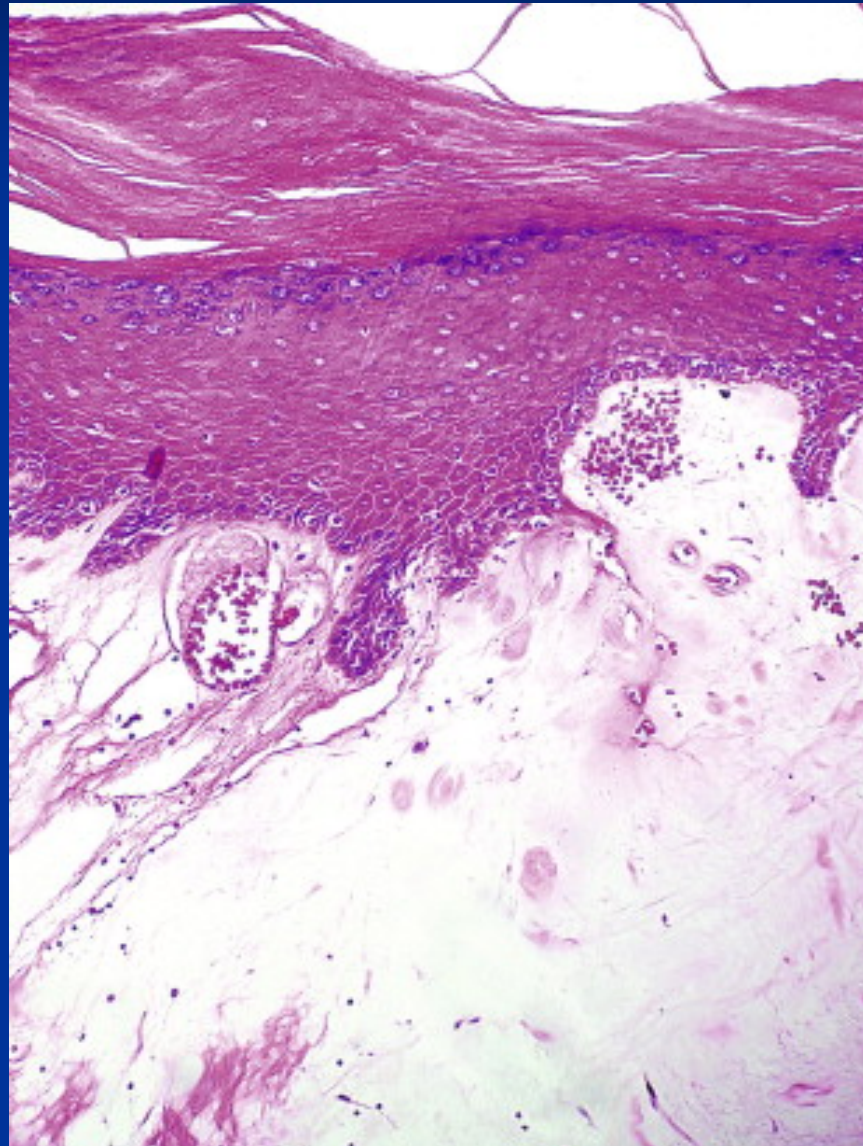
- Epidermal thinning with follicular plug
- Hyalinization within papillary dermis associated with edema
- Lichenoid infiltrate with plasma cells

What are some histopathological
variants of Lichen Sclerosus?

Bullous Lichen Sclerosus



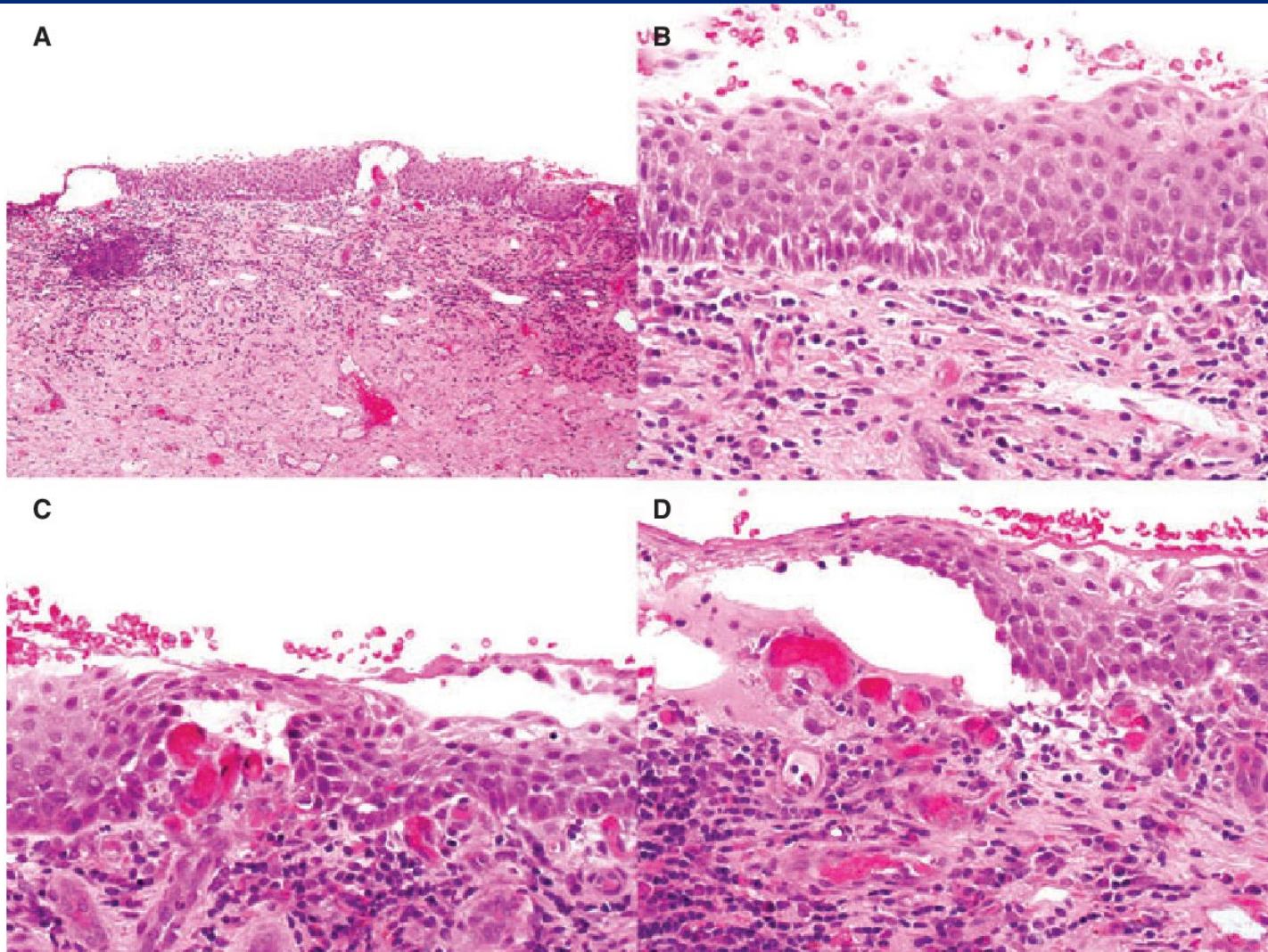
Hyperkeratotic Lichen Sclerosus



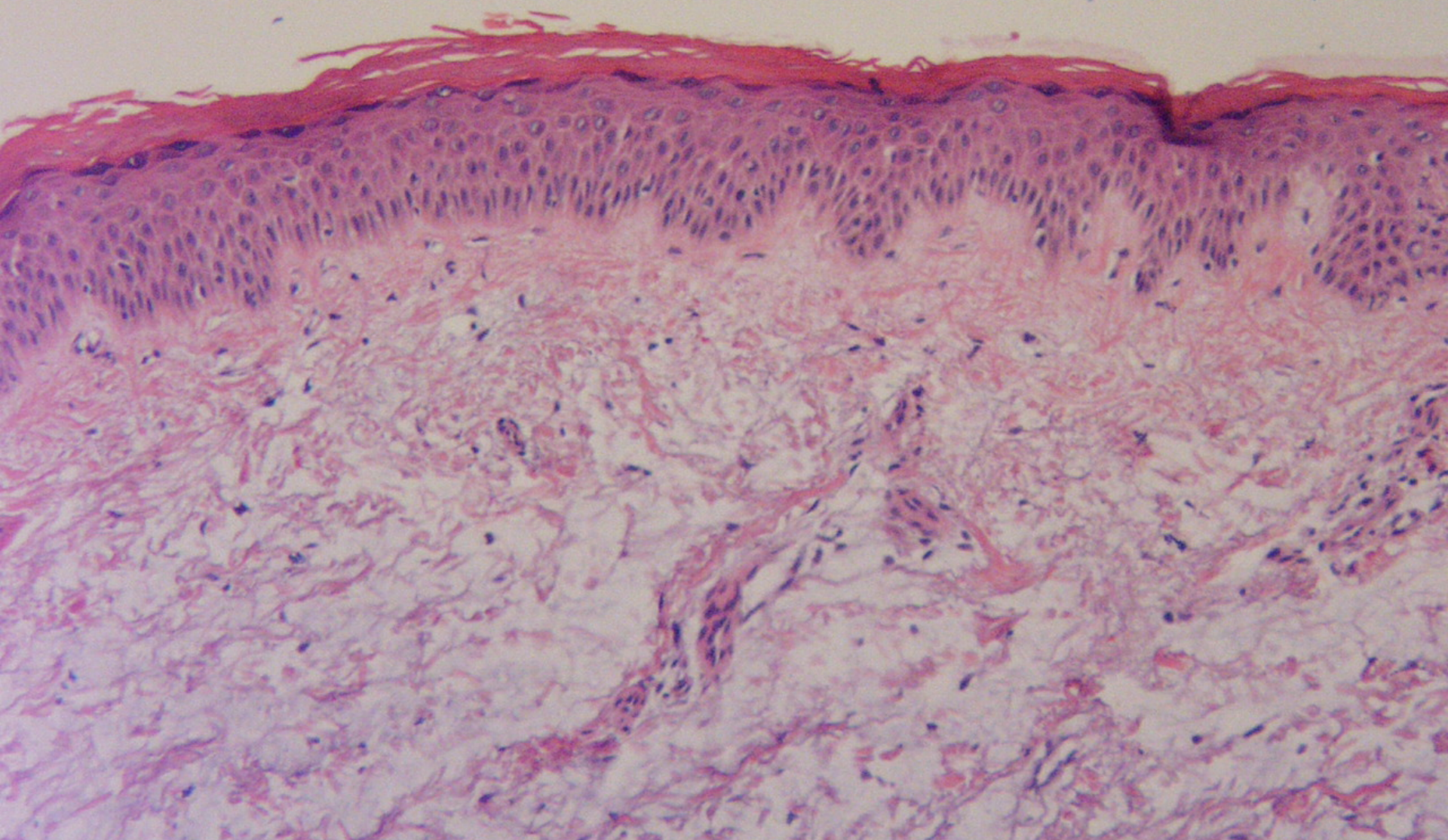
Lichen Sclerosus

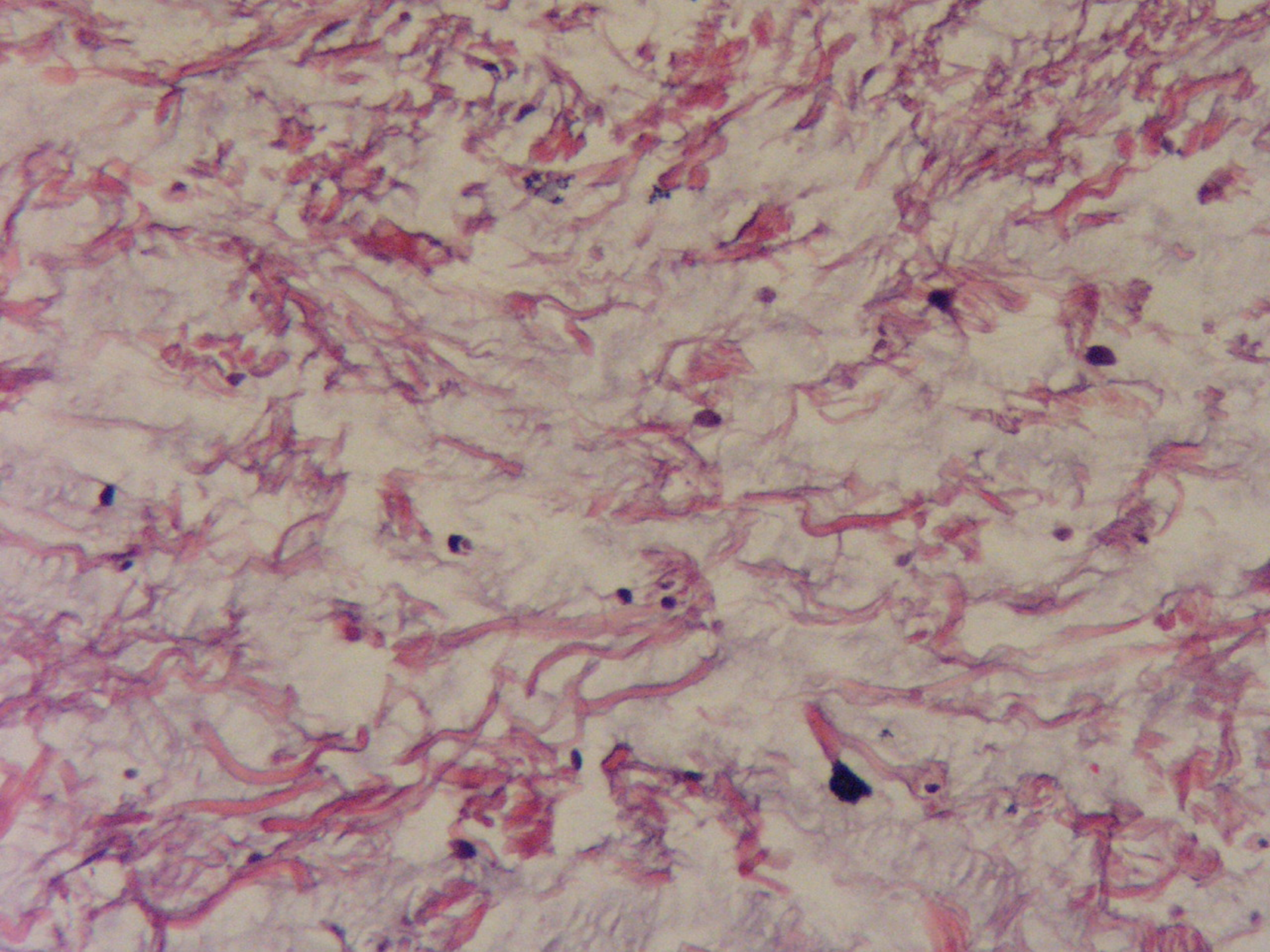
- Inflammatory phase
 - Lichenoid dermatitis, hyalinized basement membrane may be difficult to find
 - DDX: Lichen planus, fixed drug, EMLA
- Bullous
 - DDX: Autoimmune blistering disorder
- Hyperkeratotic
 - DDX: Well differentiated Vulvar squamous cell carcinoma

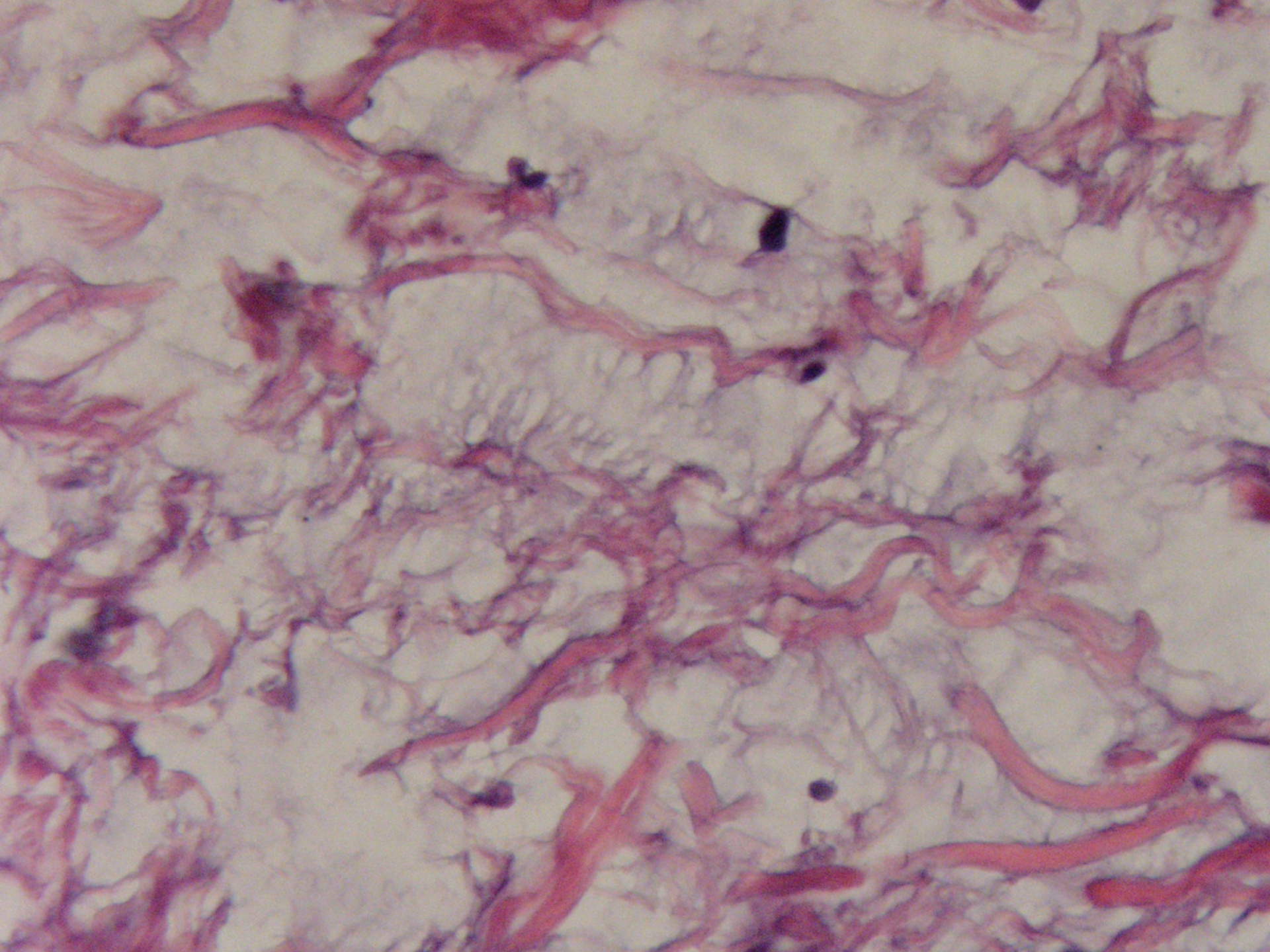
EMLA-Associated Histopathology



7 Patient 1. H&E: (A) Erosive lichen planus. There is multifocal clefting with an underlying lichenoid lymphocytic infiltrate. (B)



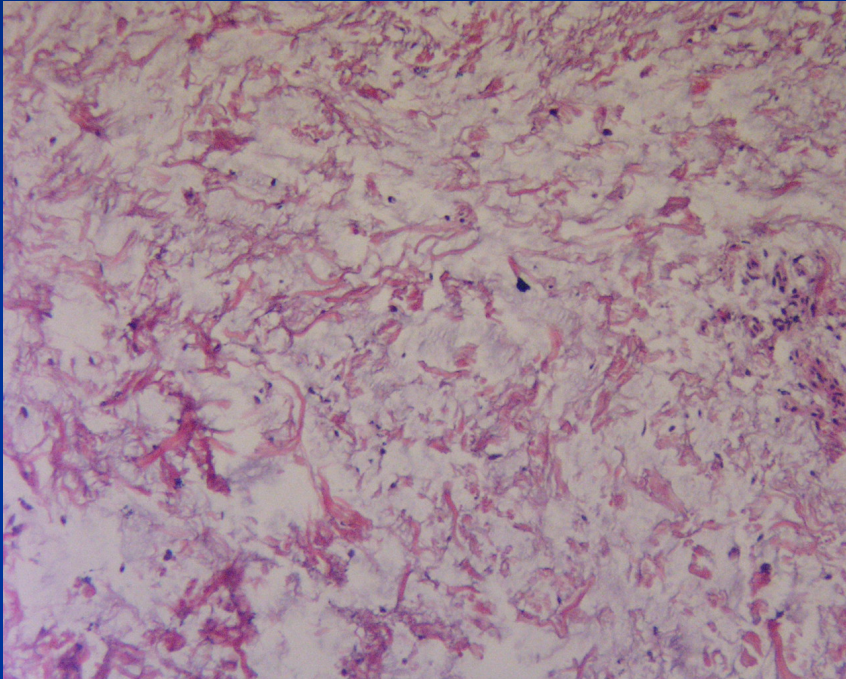




What is your differential diagnosis and what special stains/IHC would be helpful?

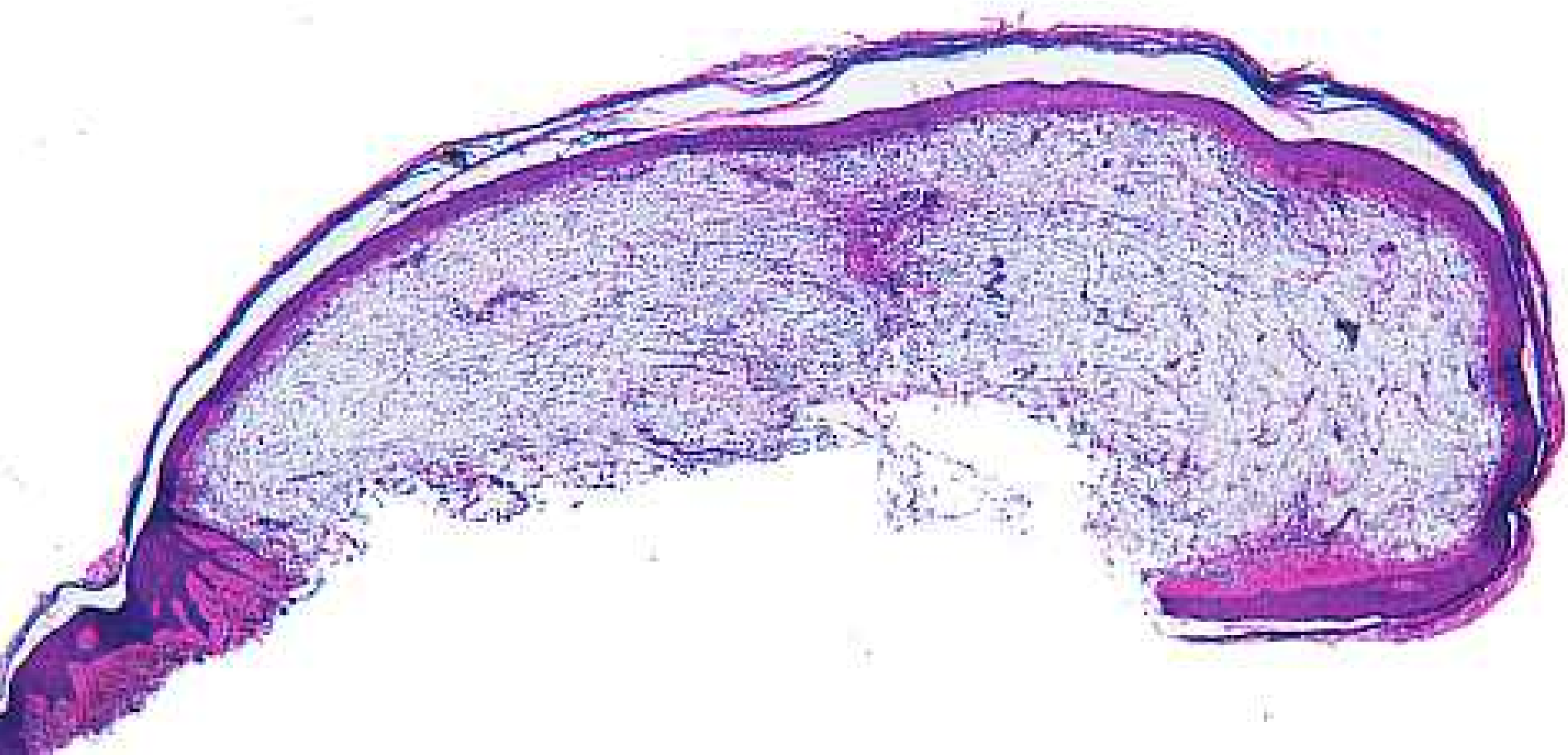Pretibial Myxedema

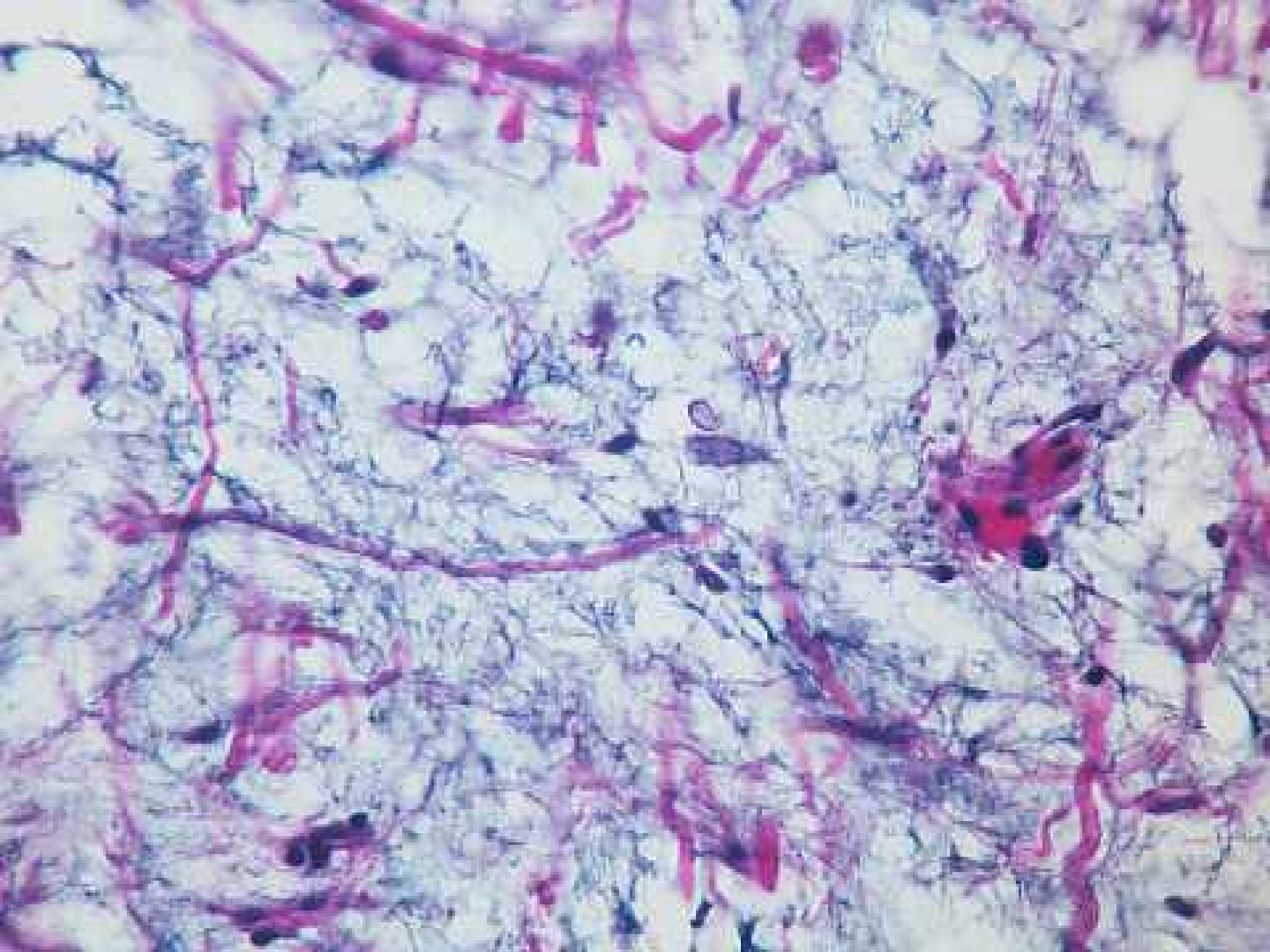
Histopathology



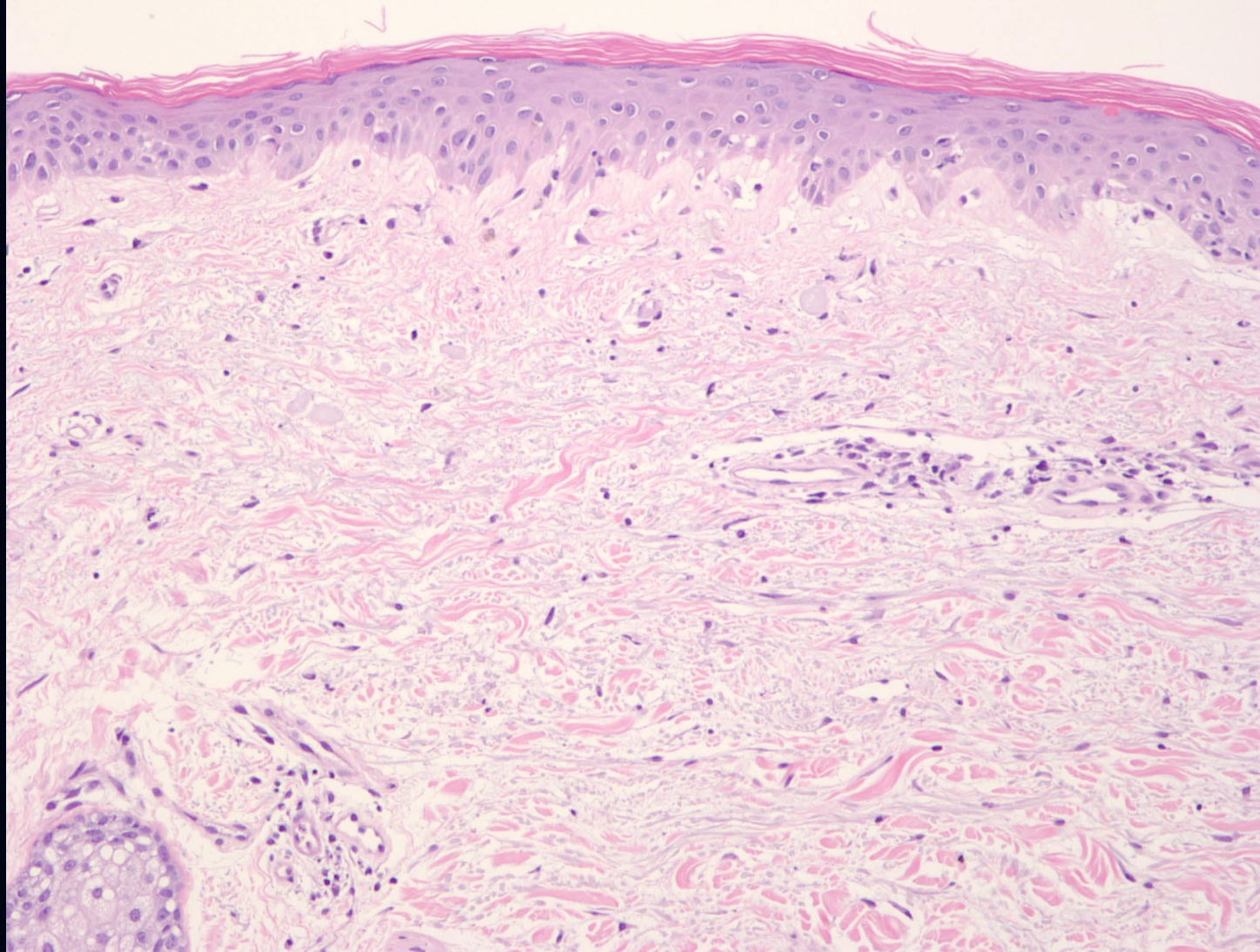
- Diffuse dermal collection of mucin
- Usually minimal inflammatory infiltrate
- Minimal to absent fibroplasia
- Clinical correlation

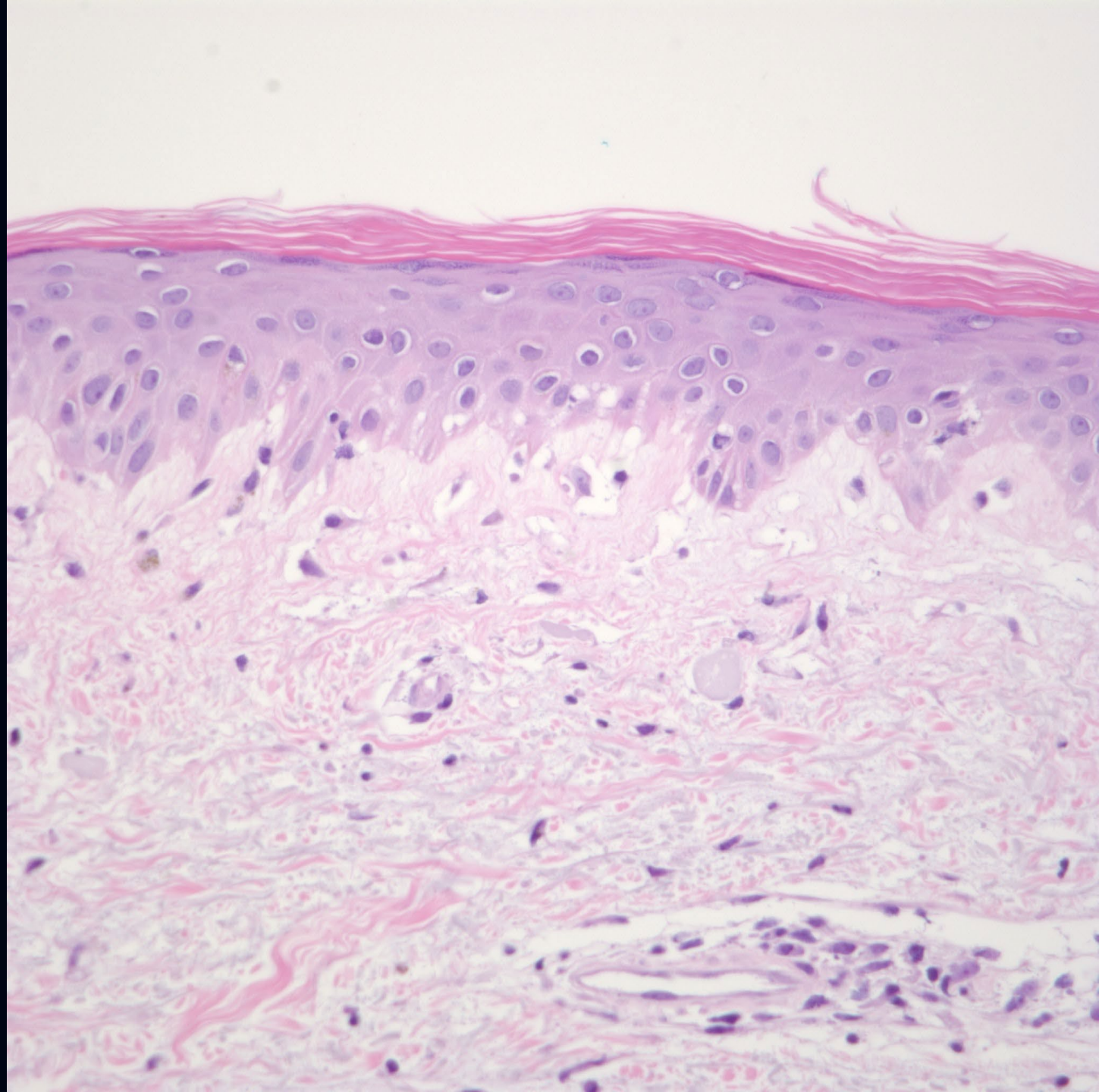
What are the following diseases
associated with dermal
mucinosis?

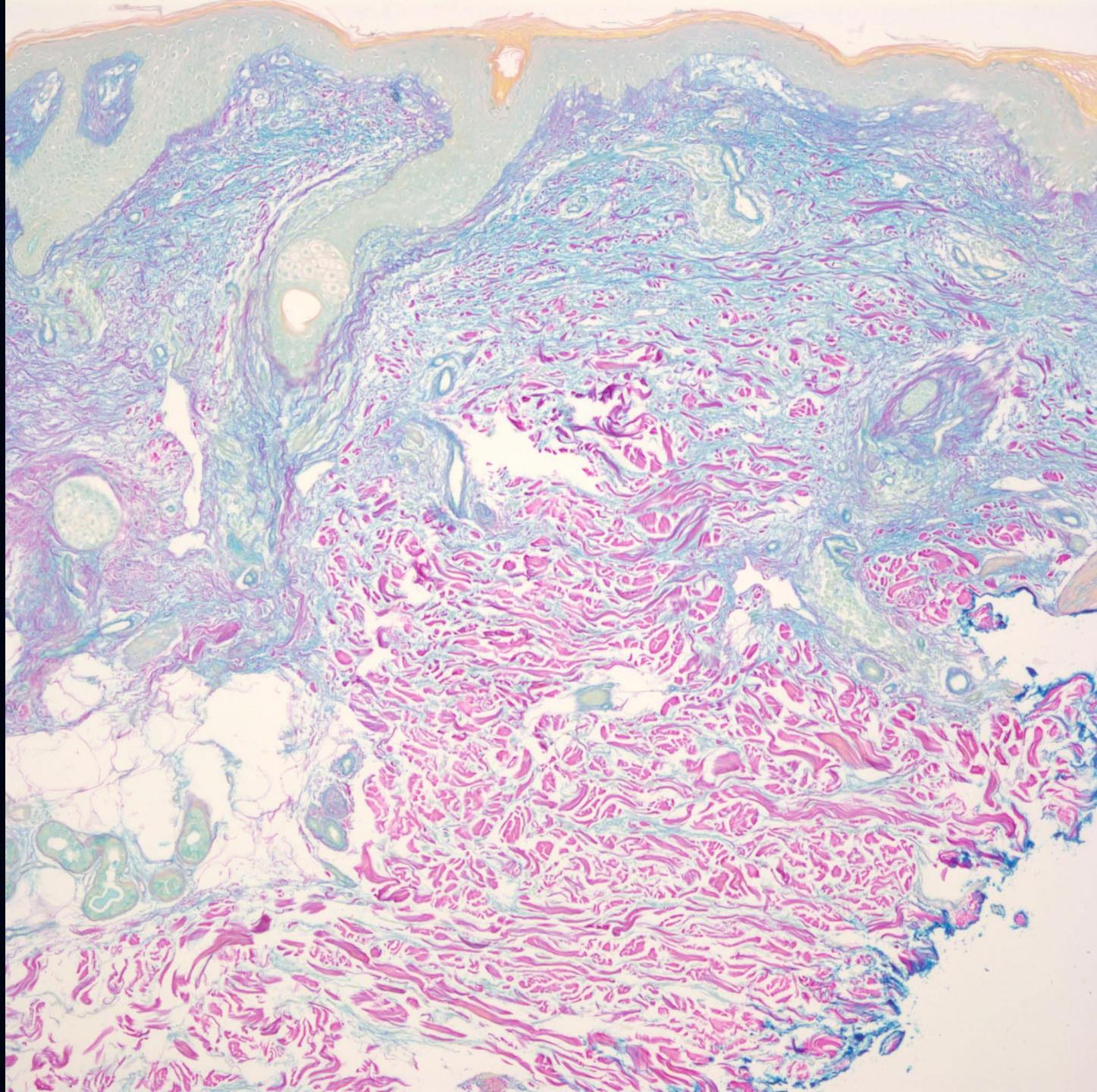




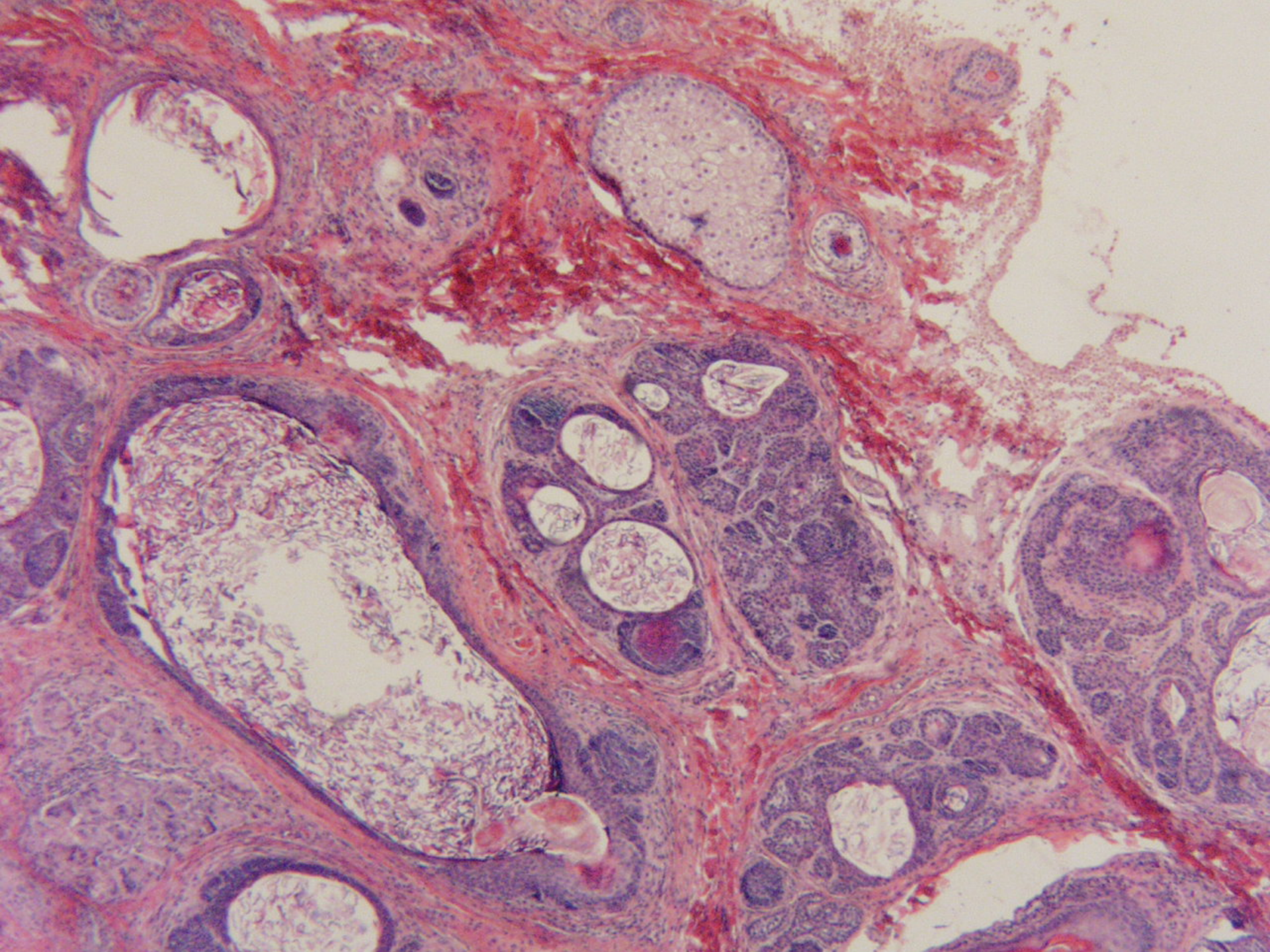
Focal Cutaneous Mucinosis

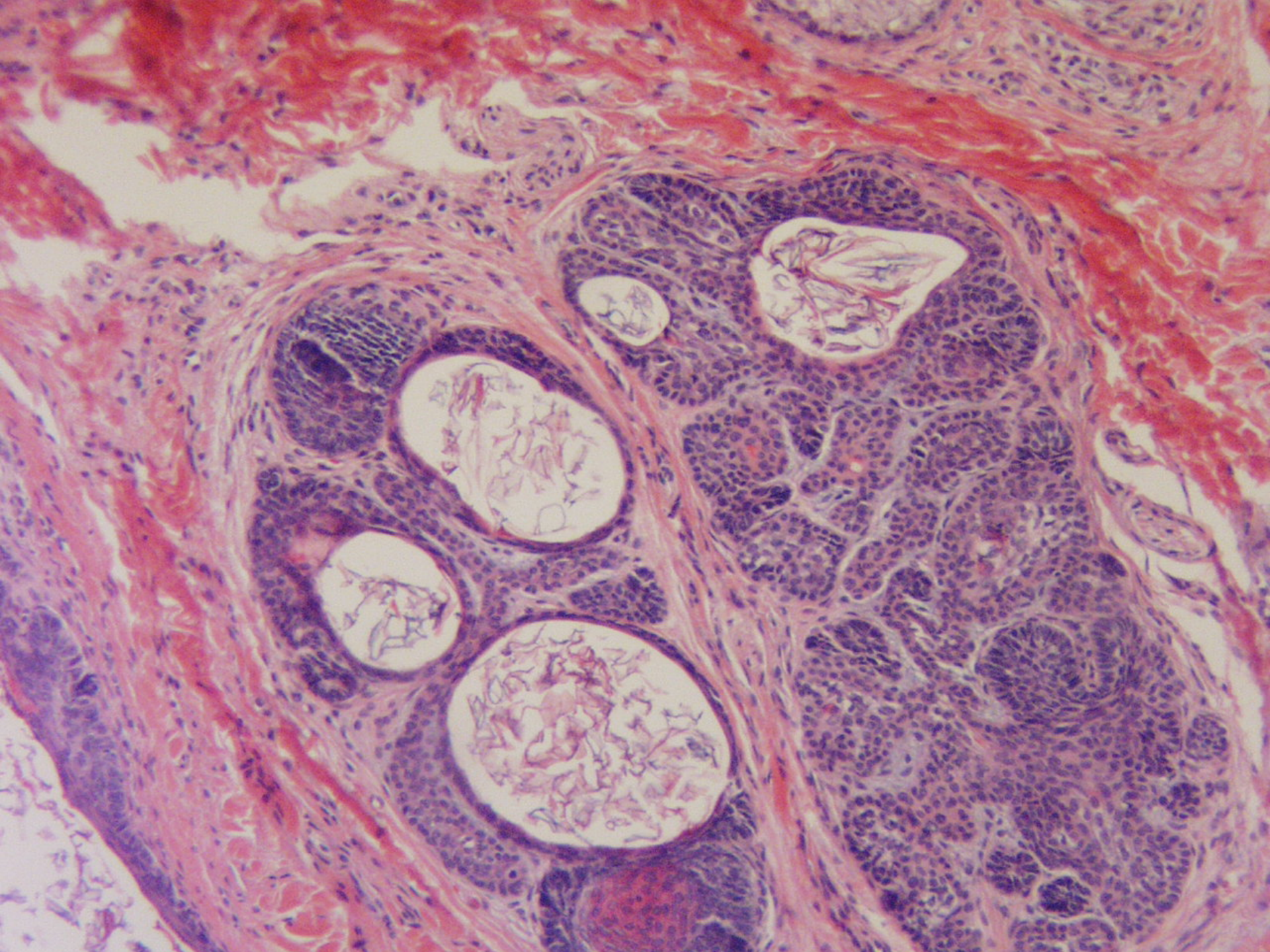


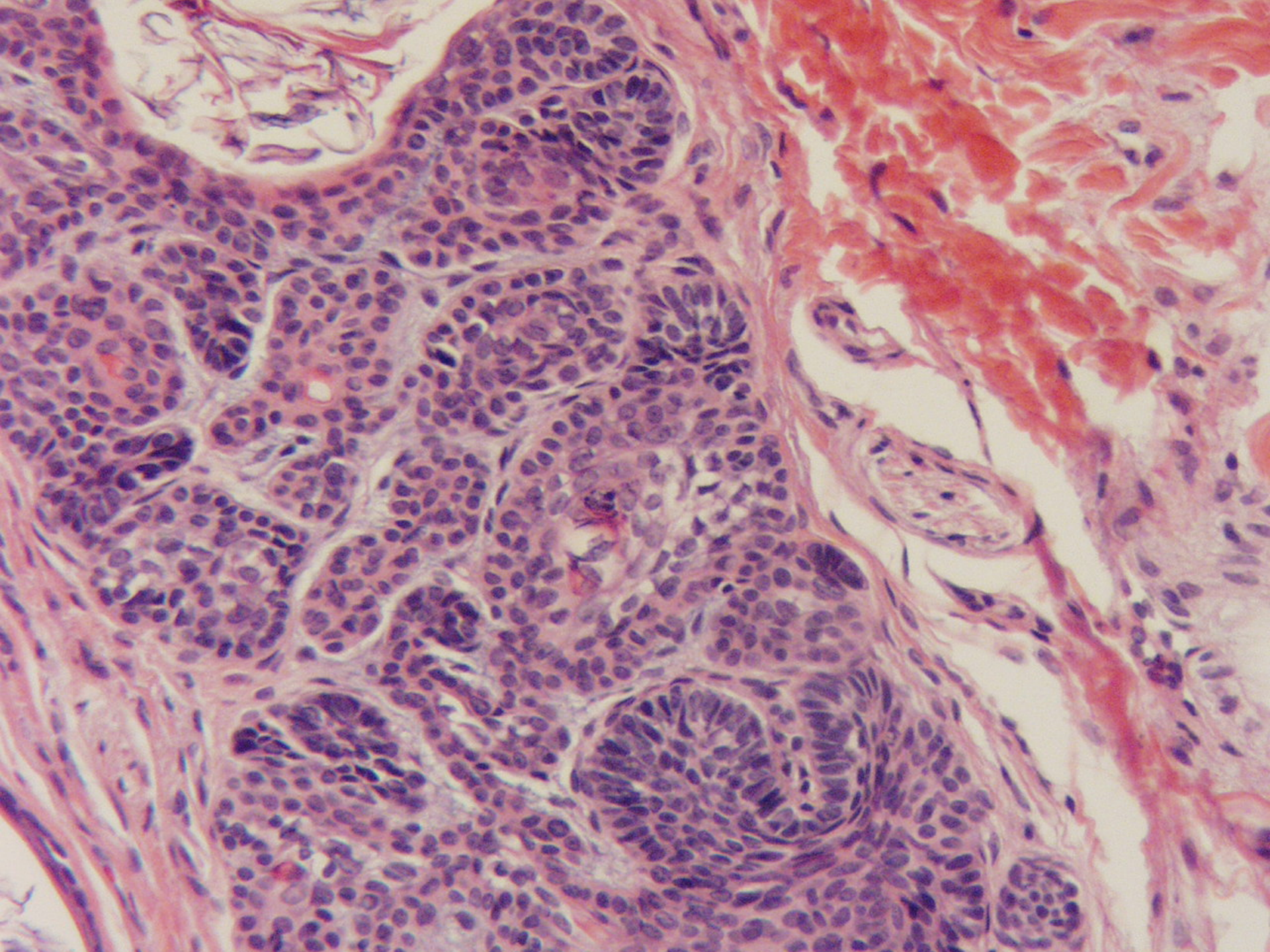


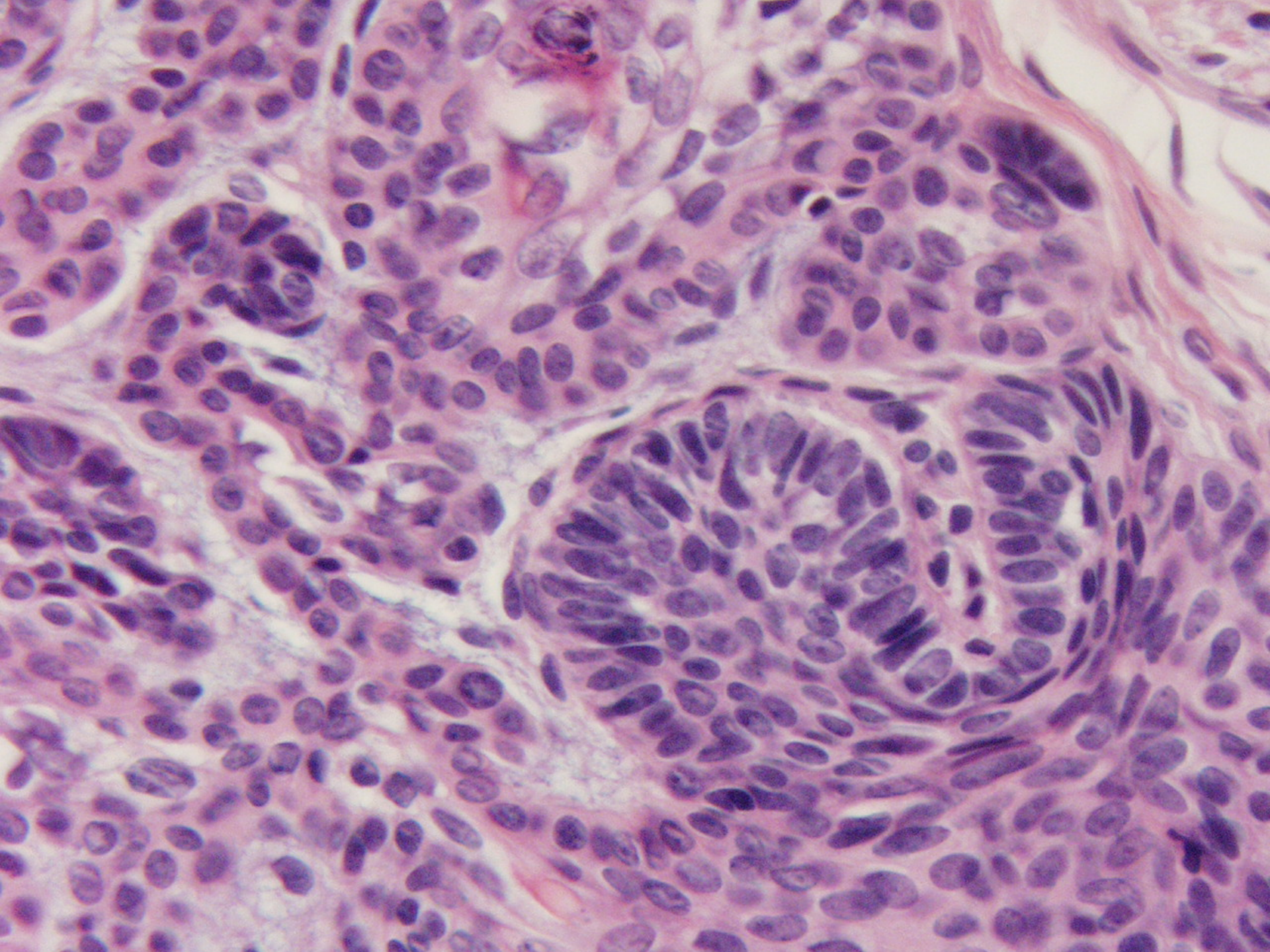


Dermatomyositis





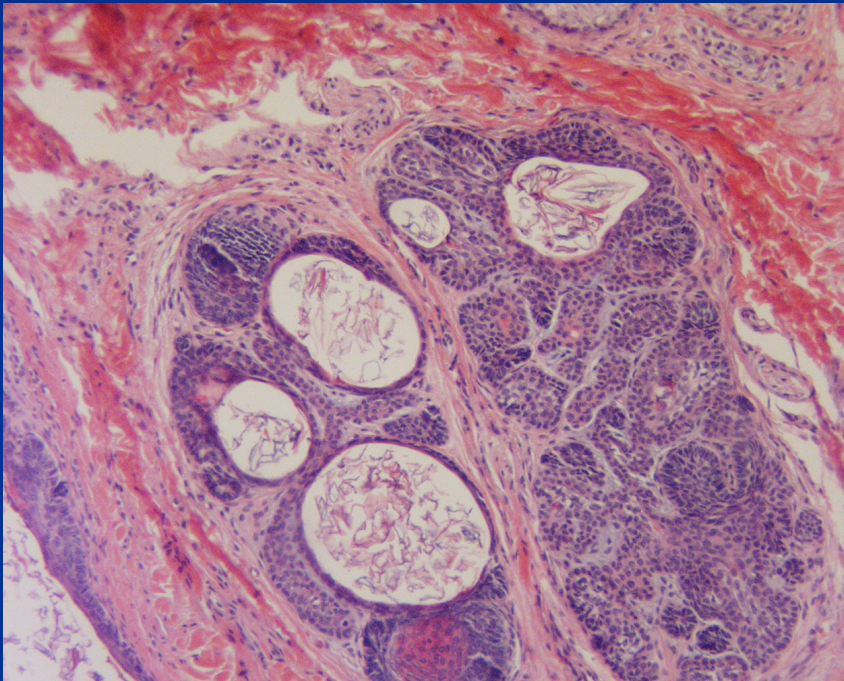




What is your differential diagnosis and what special stains/IHC would be helpful?

Trichoepithelioma

Histopathology



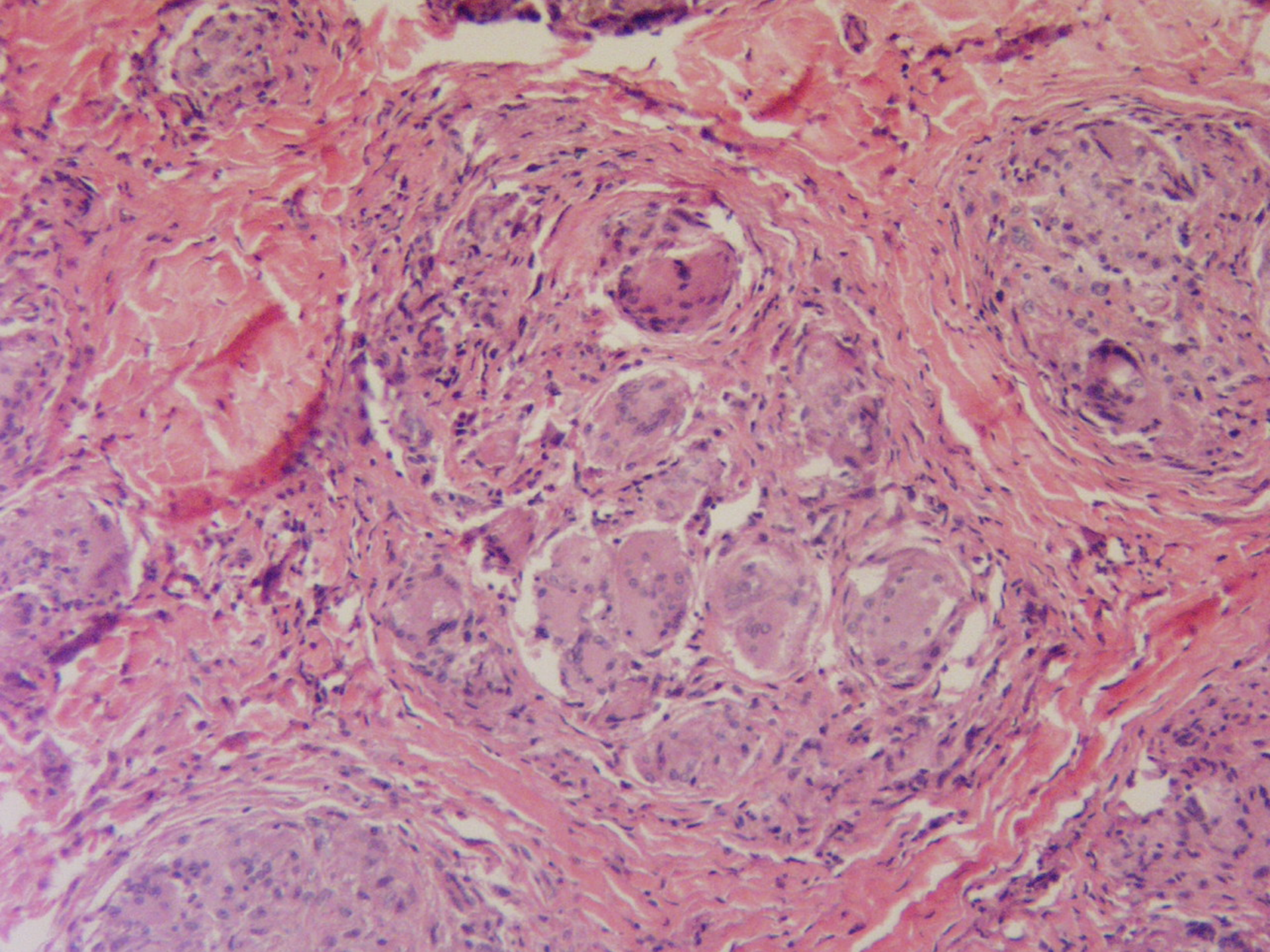
- Circumscribed dermal proliferation of follicular structures
- Usually no epidermal attachment
- Stromal-stromal clefting
- Papillary-mesenchymal bodies

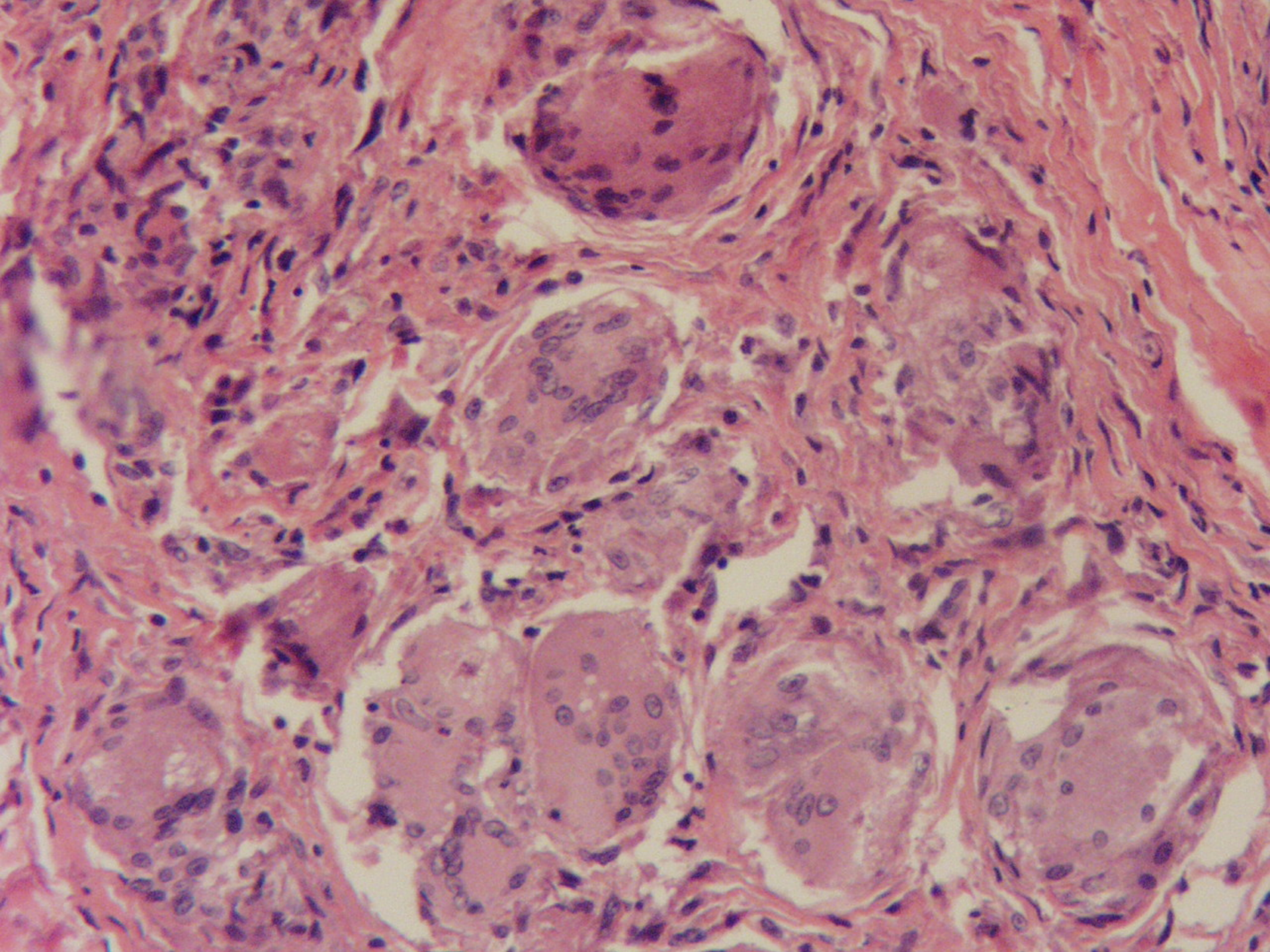
What syndromes are associated with multiple trichoepitheliomas?

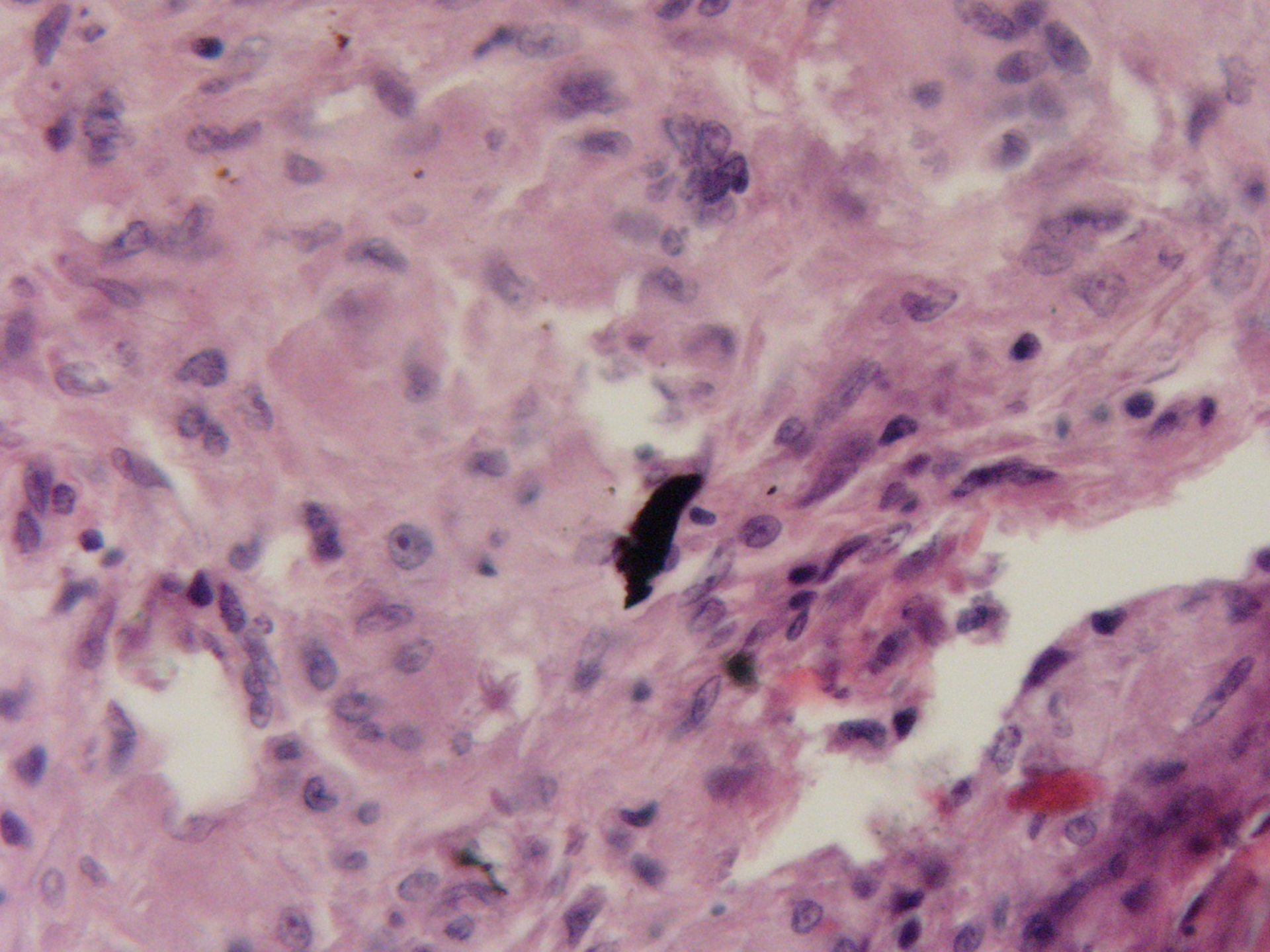
Syndromes Associated with Multiple Trichoepitheliomas

- Brooke-Spiegler syndrome
- Multiple familial trichoepithelioma
- Familial cylindromatosis

NOTE: Mutations in CYLD gene (16q12-q13) may result in each of these syndromes



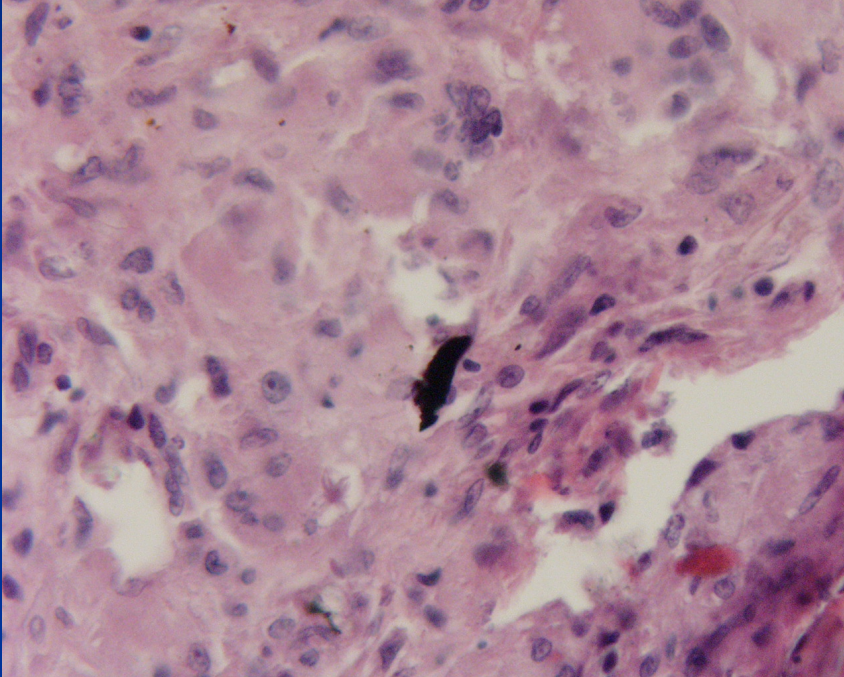




What is your differential diagnosis and what special stains/IHC would be helpful?

Foreign body granuloma with Tattoo

Histopathology



- Sarcoidal or caseating granulomas
- Always polarize
- Consider AFB/PAS
- Rule out underlying sarcoidosis

What is the differential diagnosis
of sarcoidal granulomas?

Sarcoidal Granuloma DDX

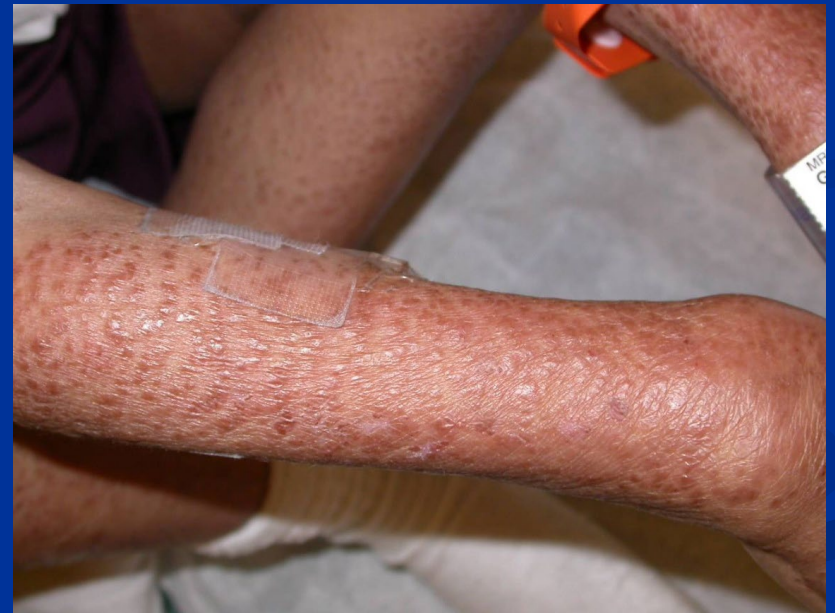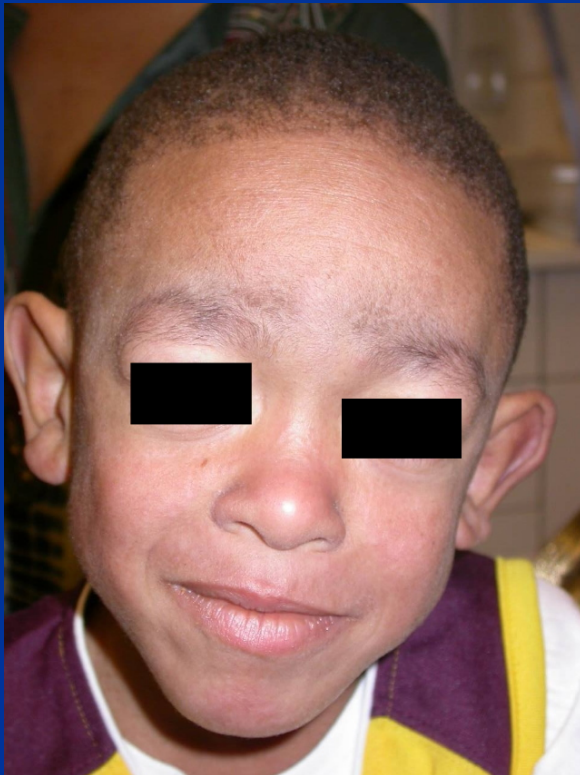- Berylliosis
- Silicosis
- Foreign body, other
- Common variable immunodeficiency
- Blau syndrome

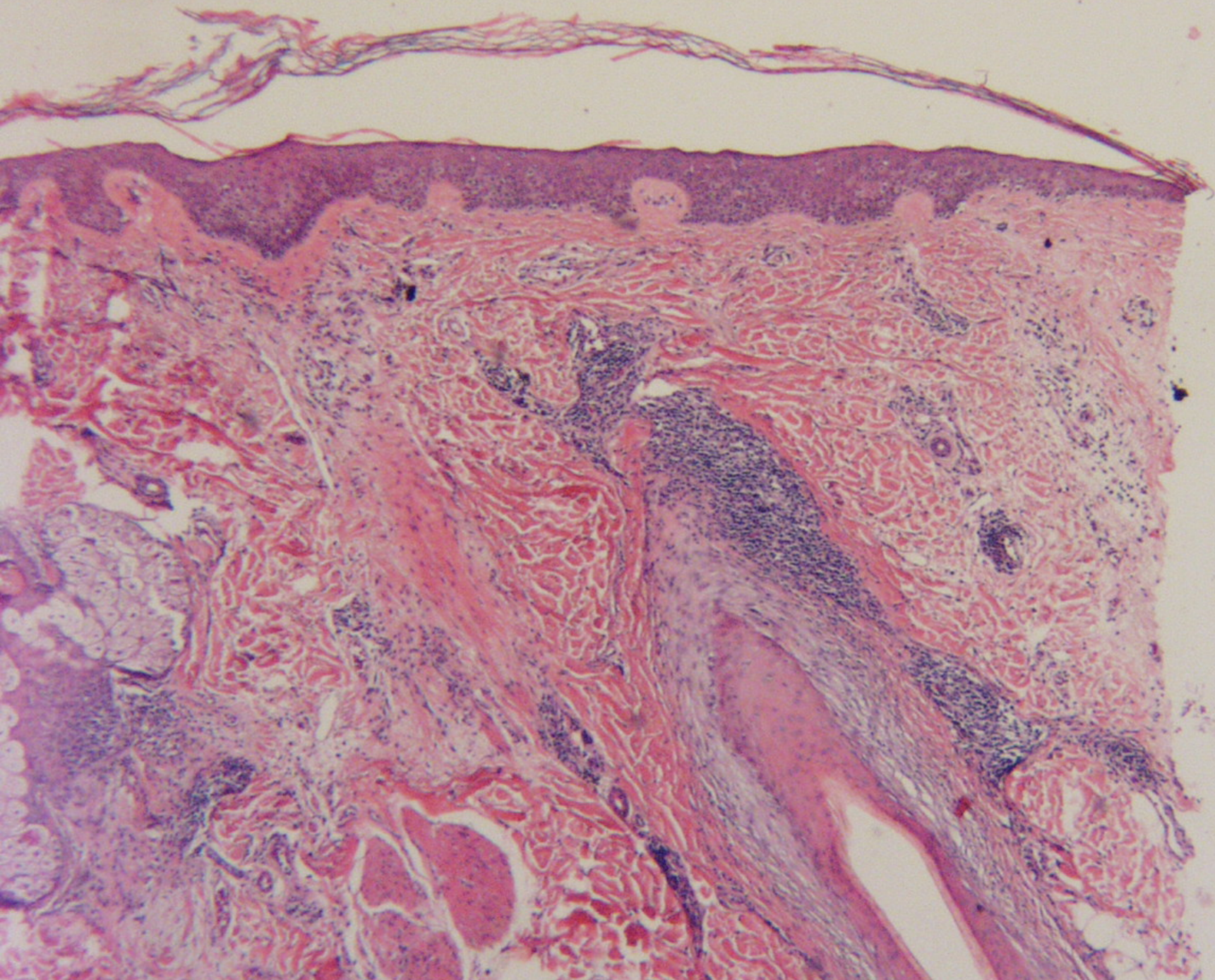
Blau Syndrome

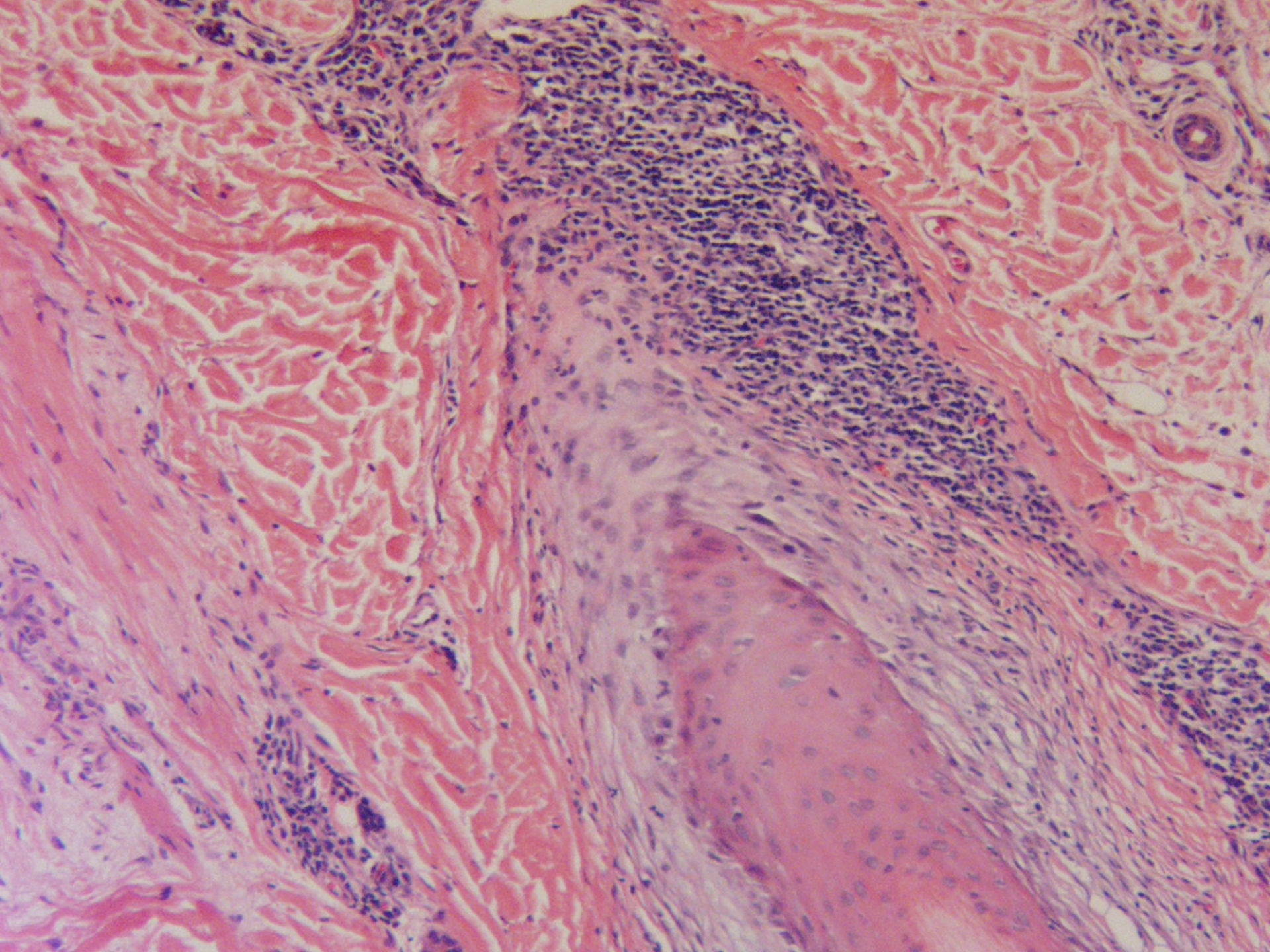
Autosomal Dominant

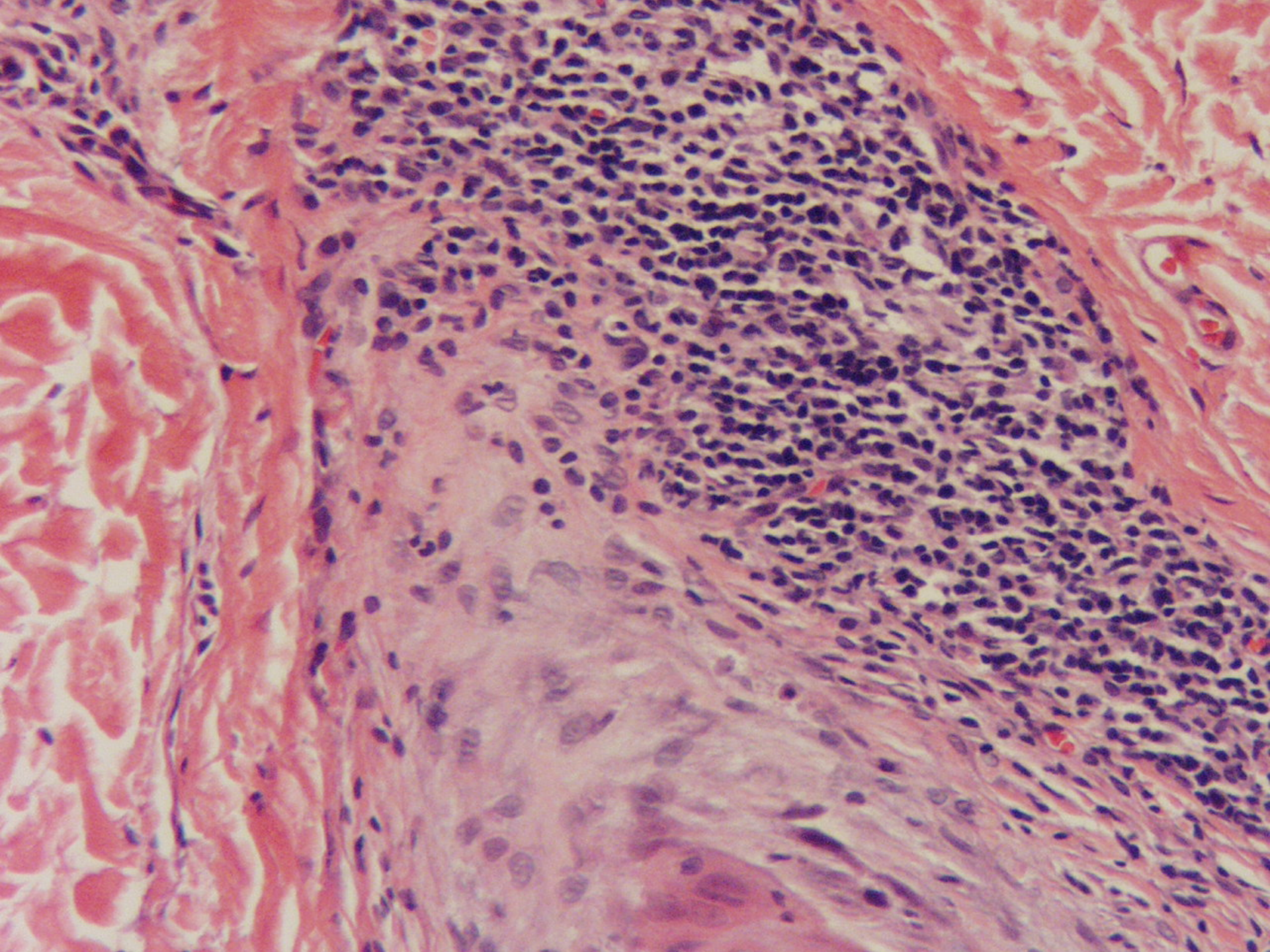
Mutation in NOD2 (CARD15)
gene

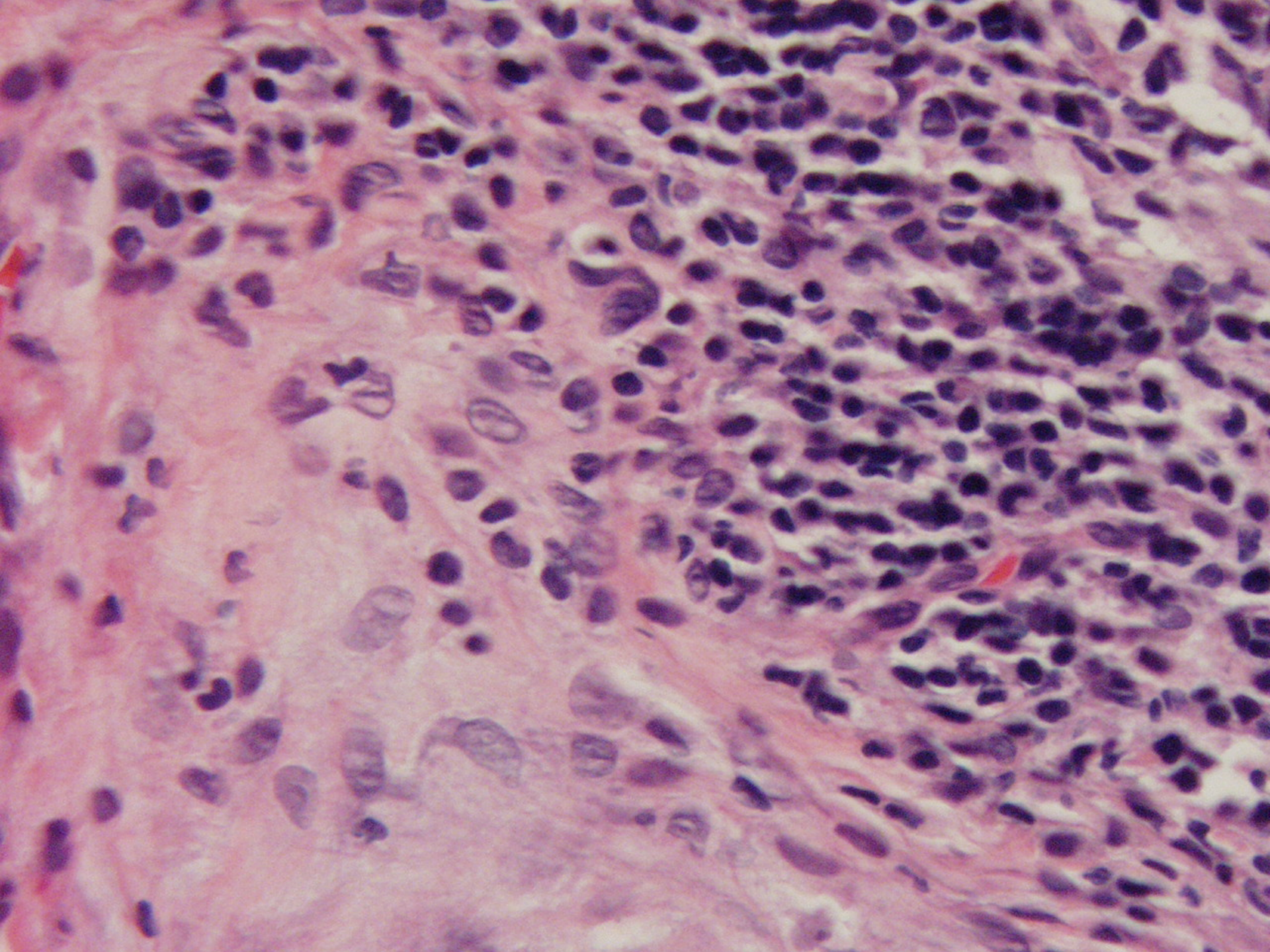
Early onset cutaneous
sarcoidosis, granulomatous
arthritis, and uveitis







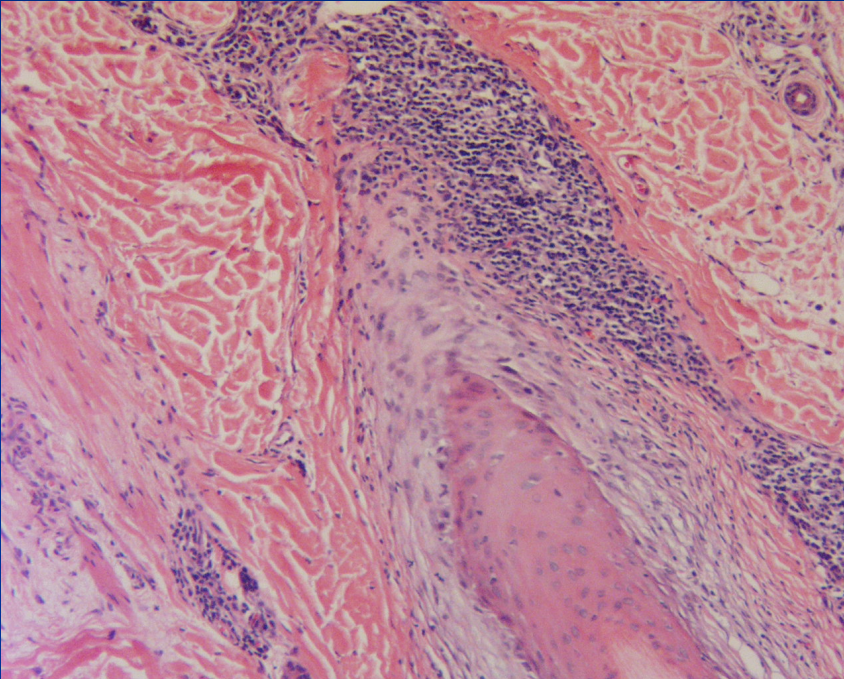




What is your differential diagnosis and what special stains/IHC would be helpful?

Lichen planopilaris

Histopathology



- Scarring alopecia
- Lichenoid infiltrate surrounding hair follicles
- May not show epidermal involvement

What are two
clinical/pathological variants
of lichen planopilaris?

Clinical-Pathologic Variants of Lichen Planopilaris

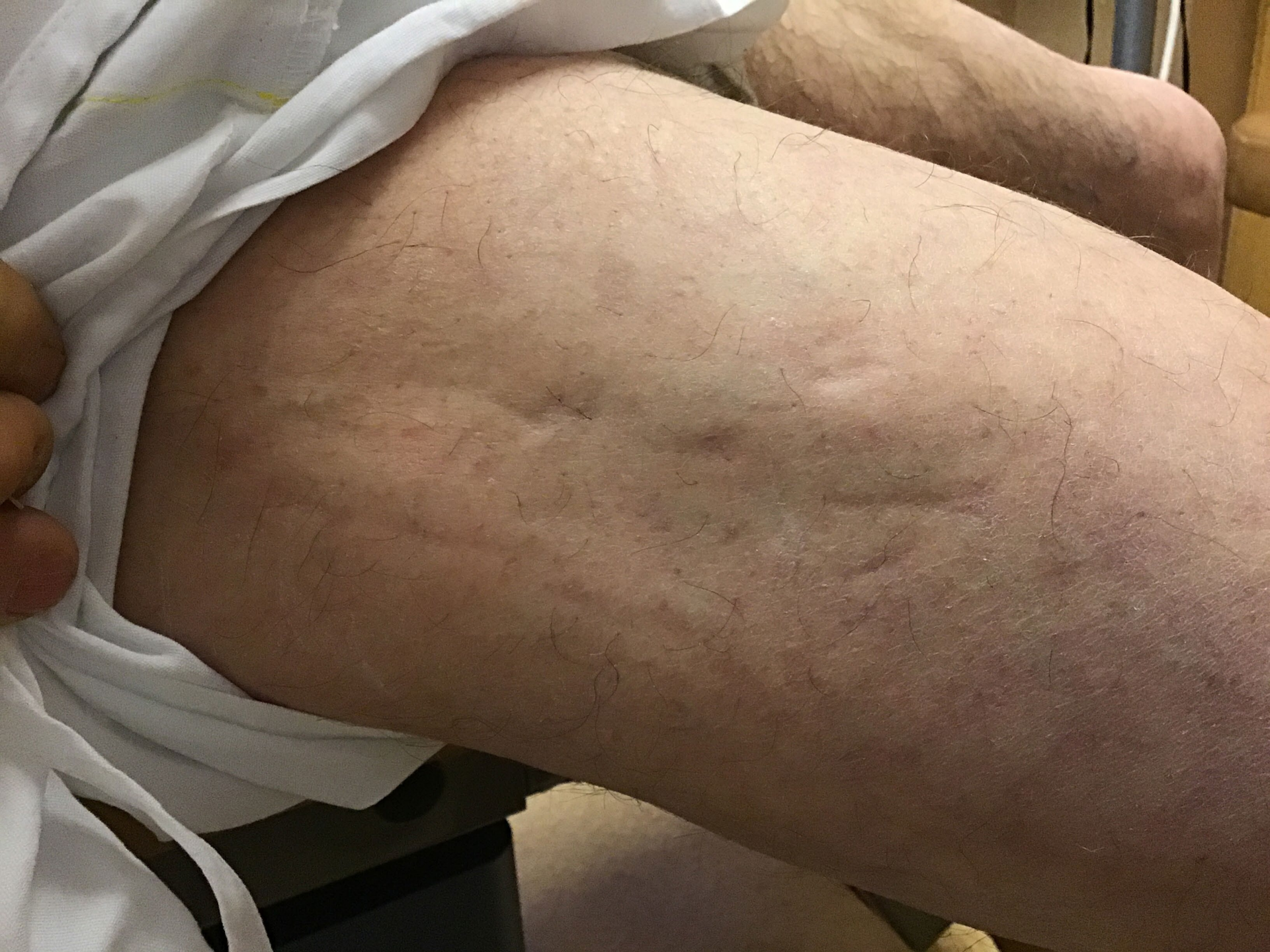■ Graham-Little Syndrome

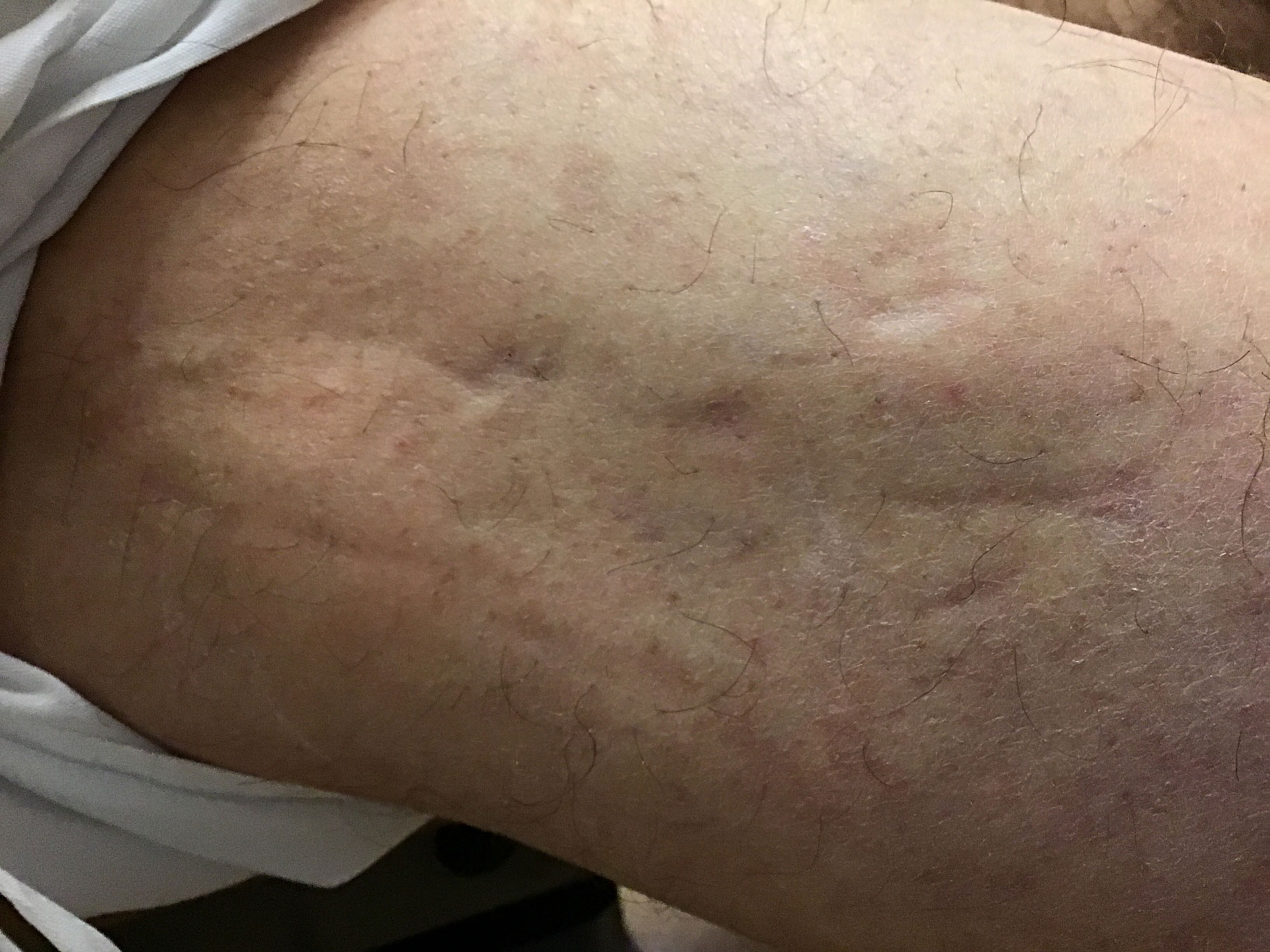- Progressive patchy scarring hair loss of the scalp
- Nonscarring thinning of the hair in the armpits and groin
- Spiky rough bumps based on hair follicles (lichen spinulosa, keratosis pilaris)

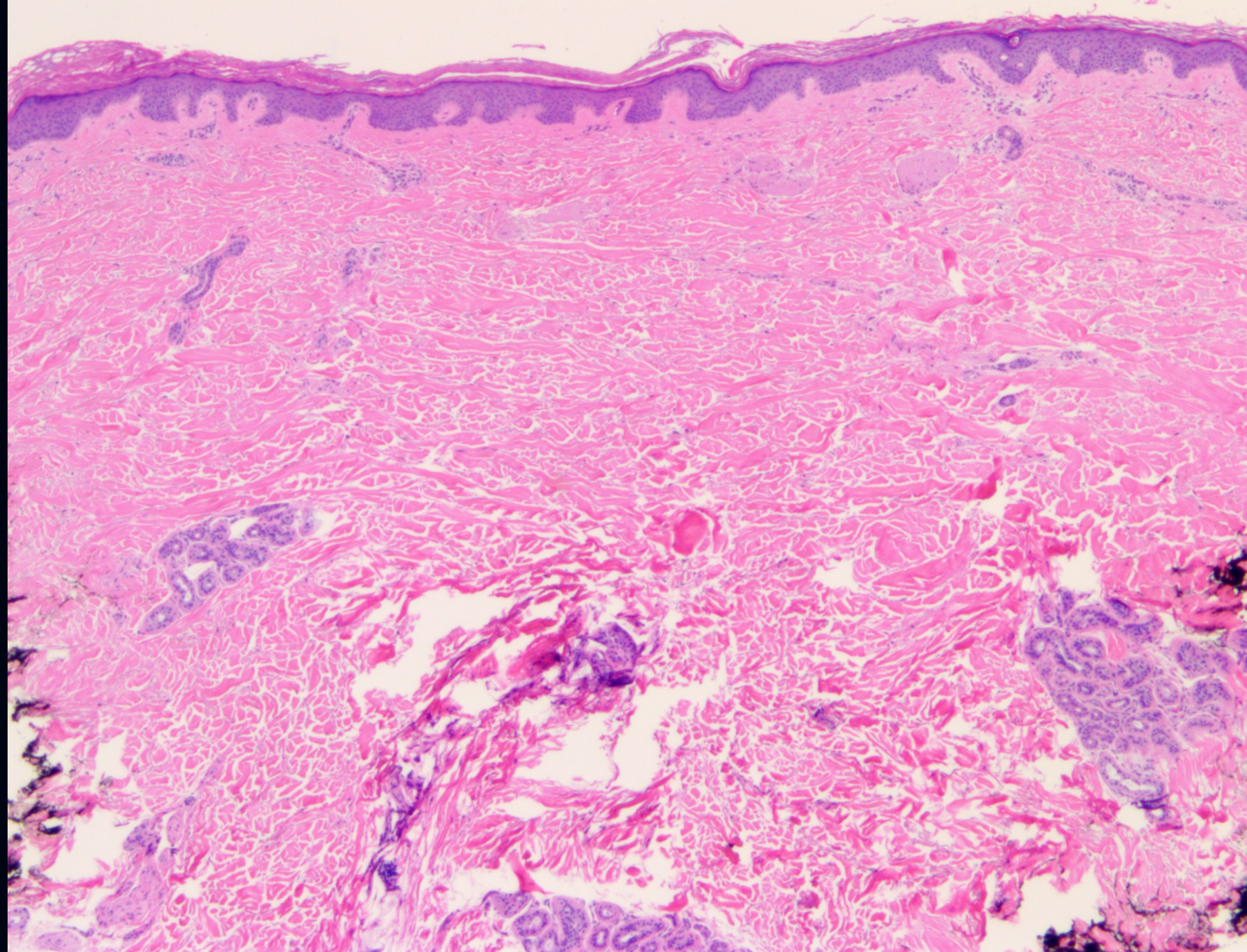
■ Frontal Fibrosing Alopecia

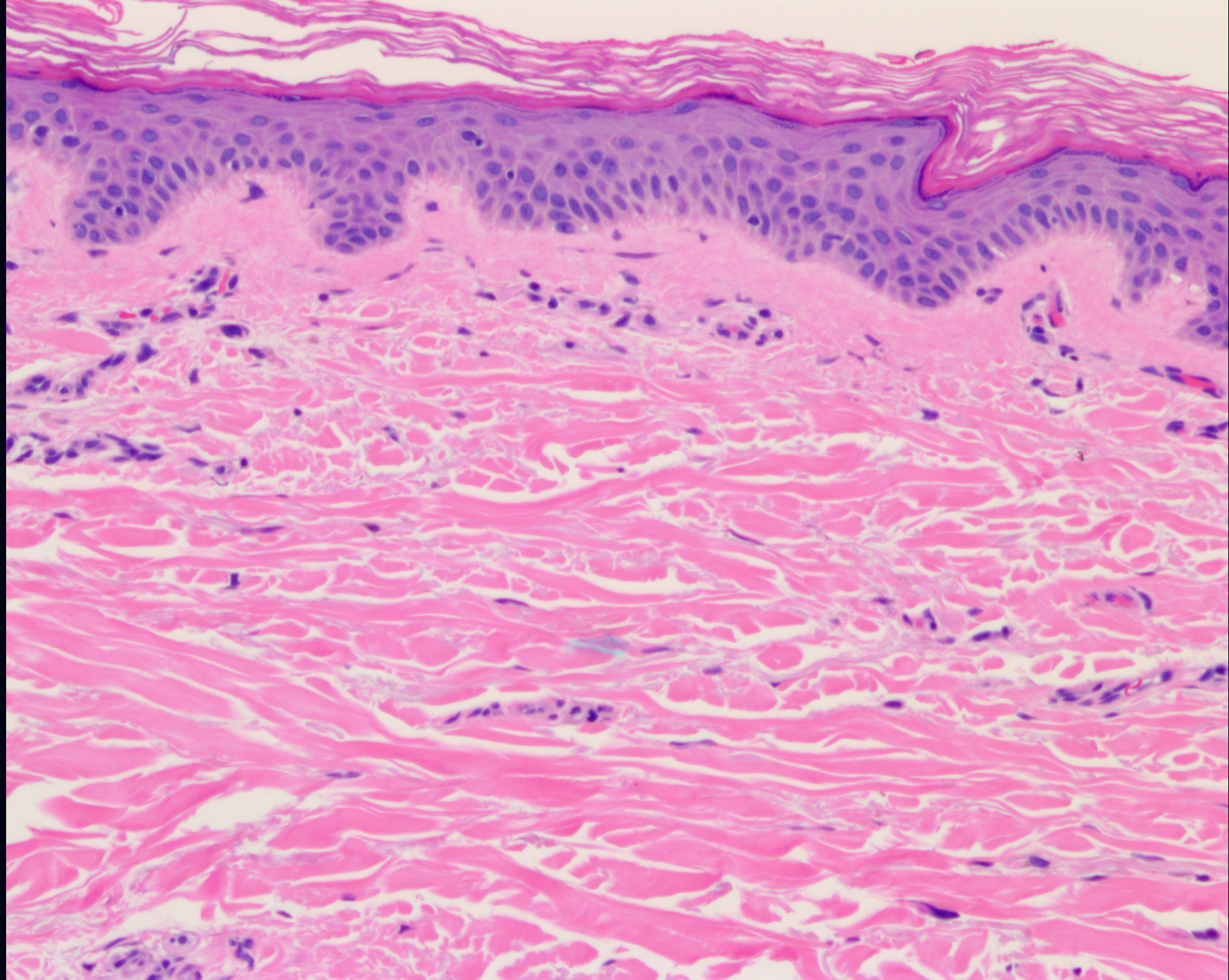
- Localized variant in frontal region of scalp
- Usually post-menopausal women

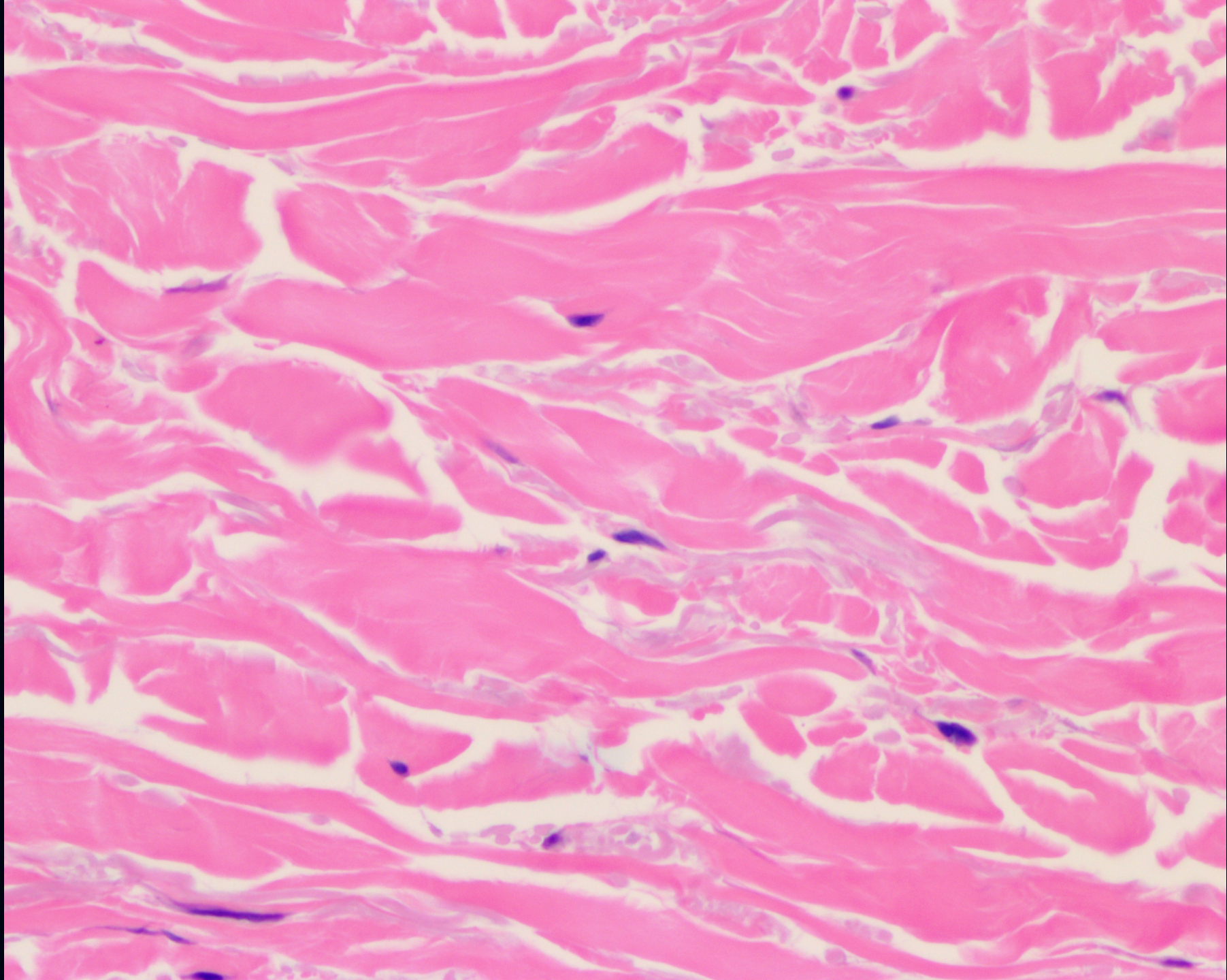
67 y.o. M with bilateral firm
plaques on thighs. S/P BM
transplant 25 years ago







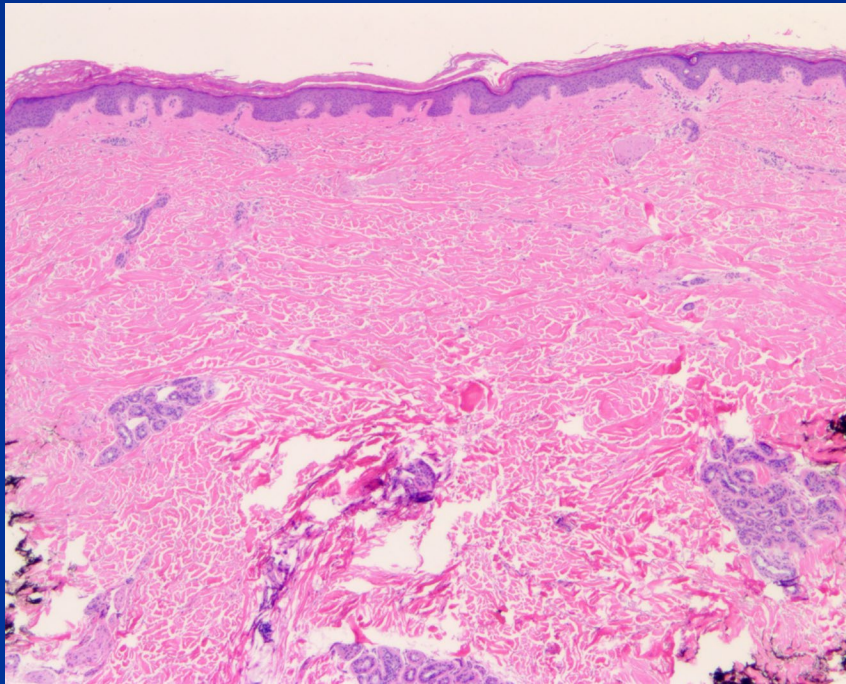




What is your differential diagnosis and what special stains/IHC would be helpful?

Chronic Graft Versus Host Disease

Chronic Graft Versus Host Disease



- Clinical-pathological correlation
- Non-specific findings with dermal sclerosis and minimal inflammatory cell infiltrate
- May see flattening or atrophy of the epidermis
- DDX:
Morphea/Scleroderma,
chronic radiation changes,
scar

**What are the classic
histopathologic stages of Graft
vs. Host Disease-Acute and
Chronic?**

Graft Vs. Host Disease-Acute

- Grade 0
 - Normal skin
- Grade 1
 - Basal vacuolar change
- Grade 2
 - Dyskeratotic cells in the epidermis and/or follicle, dermal lymphocytic infiltrate-Satellite cell necrosis
- Grade 3
 - Fusion of basilar vacuoles to form clefts and microvesicles
- Grade 4
 - Separate of epidermis from dermis

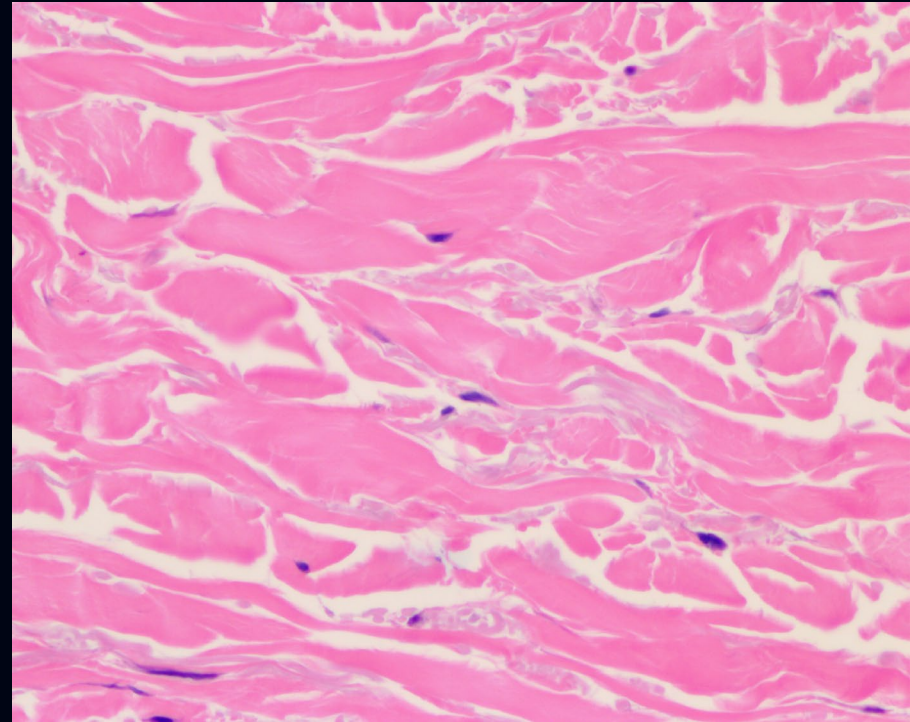
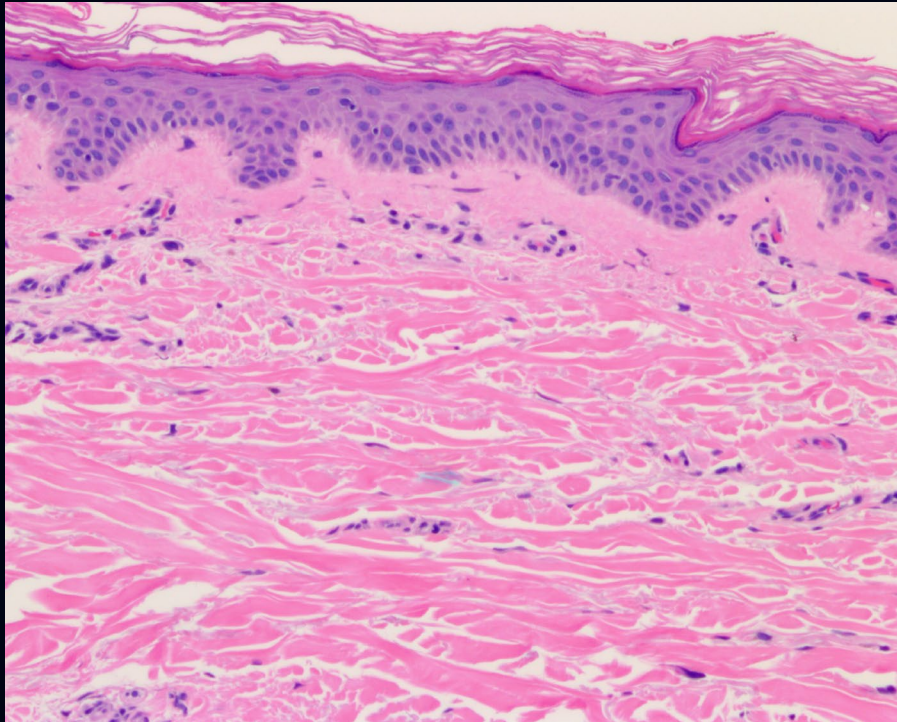
Graft Vs. Host Disease-Chronic

- Lichenoid dermatitis
- DIF with IgM and C3 in colloid bodies

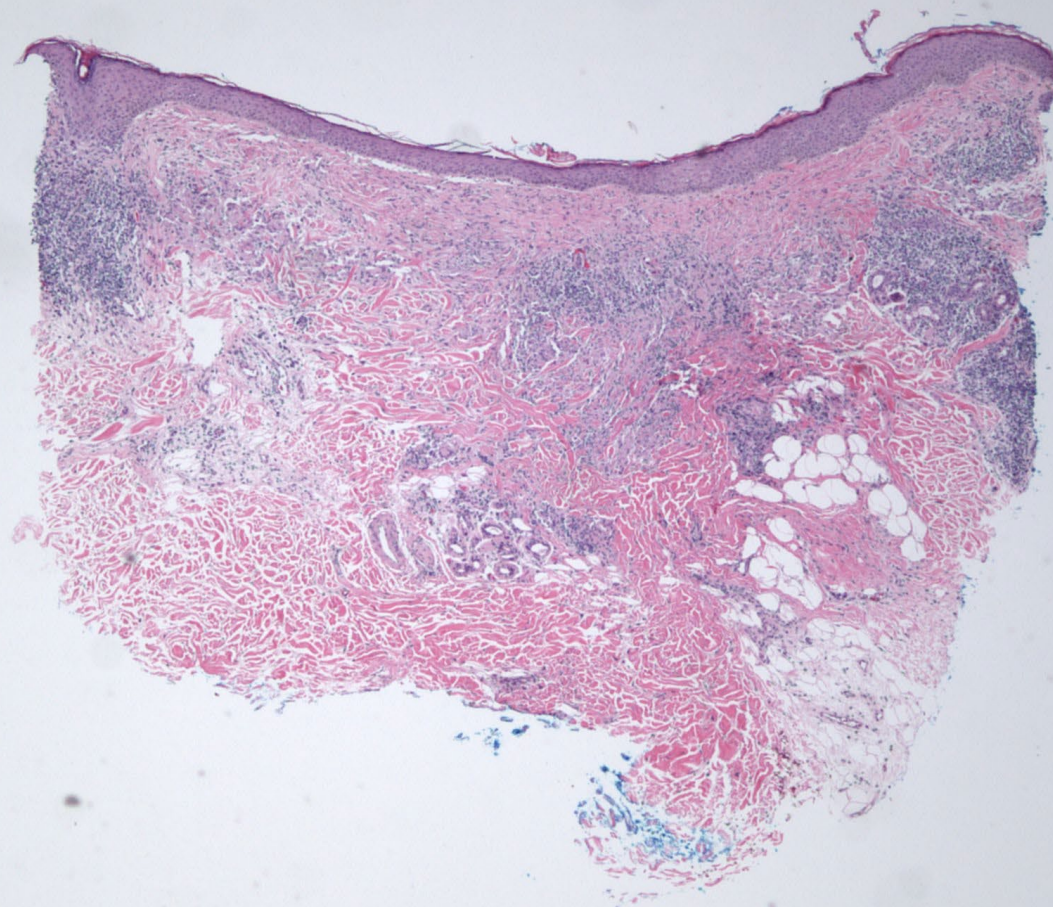
Graft Vs. Host Disease- Late Sclerodermoid phase

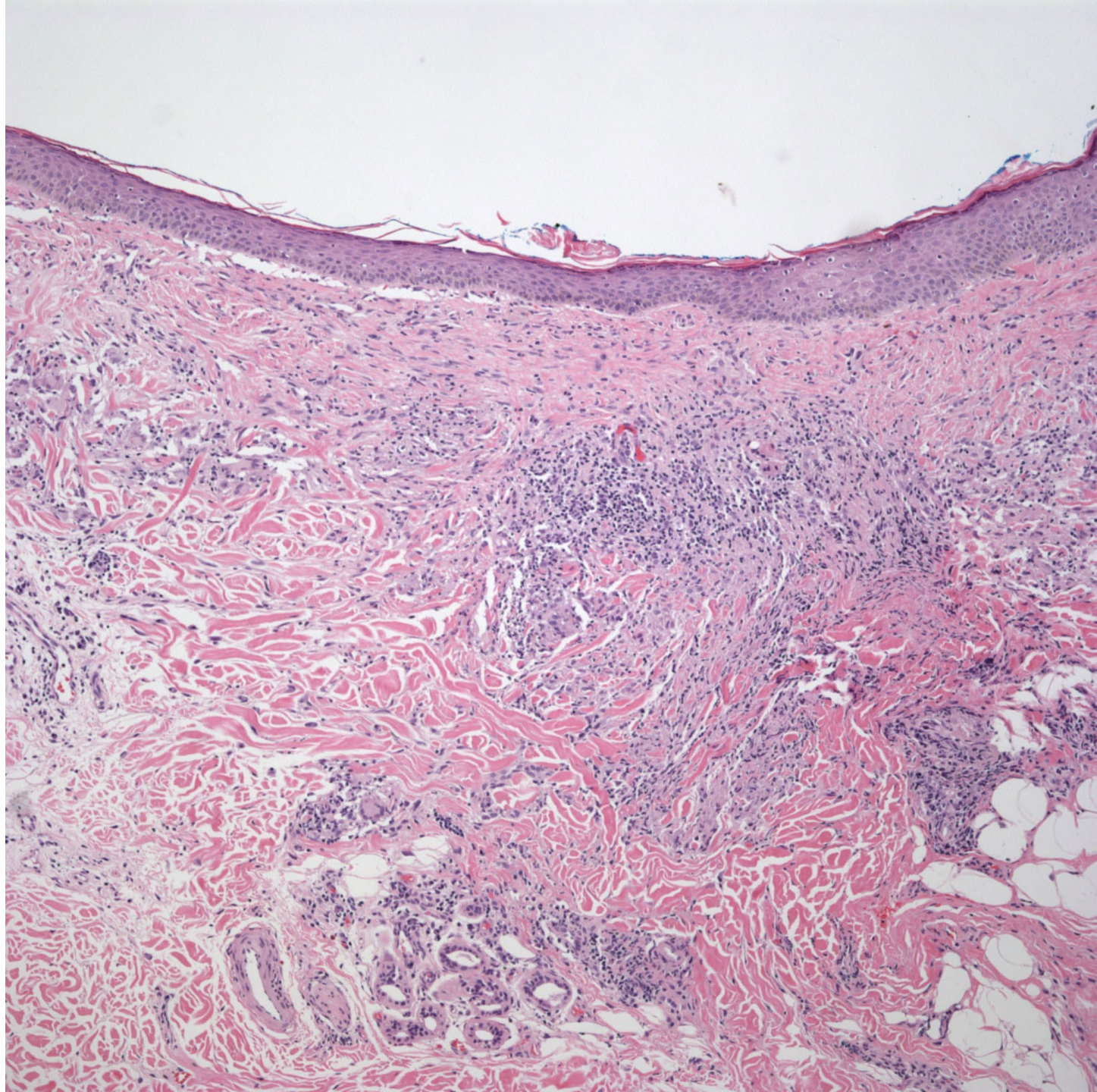
- Mild epidermal changes with atrophy and basal vacuolation
- Thickening of dermal collagen bundles
- Atrophy of skin appendages

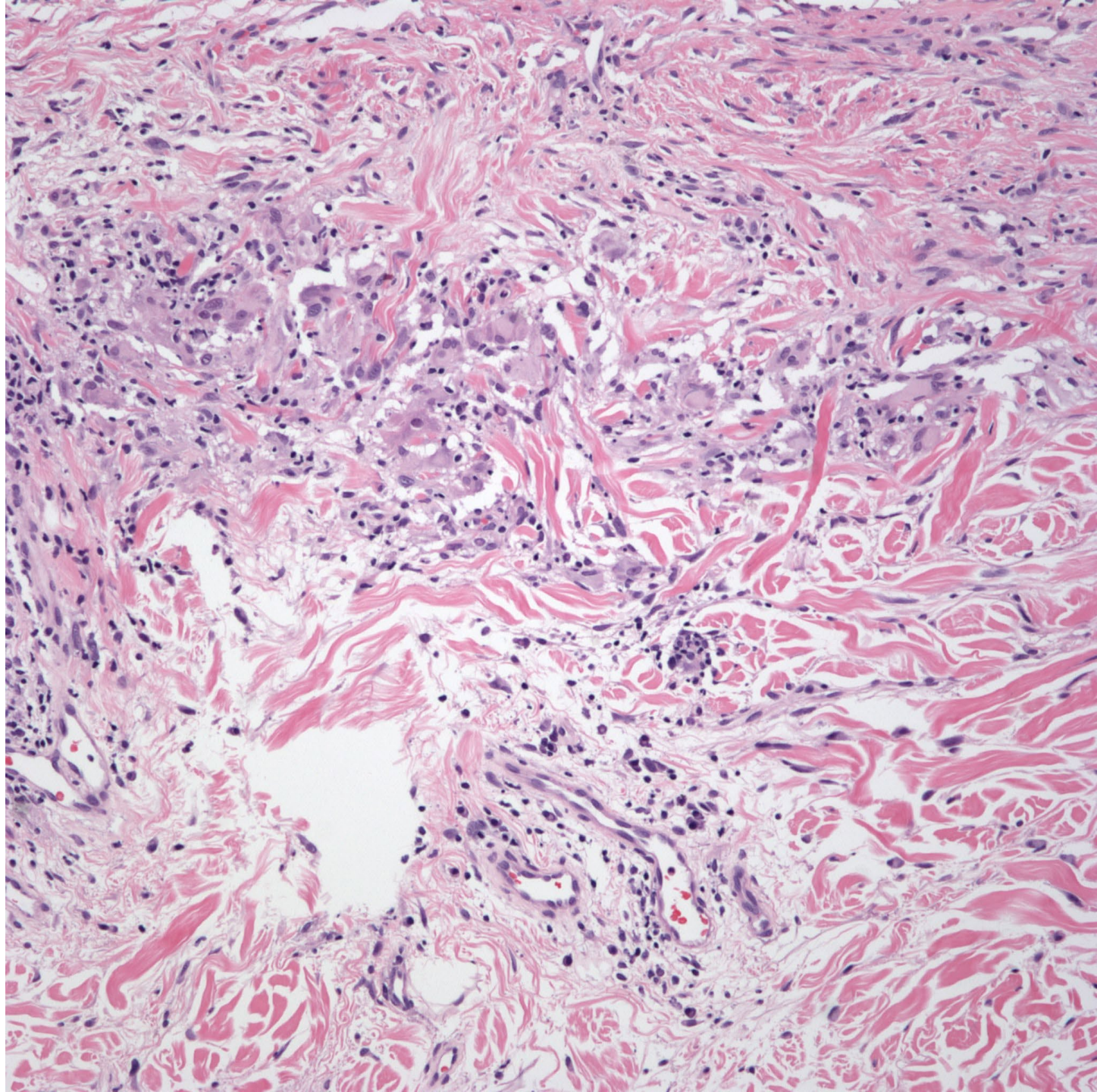
Graft Vs. Host Disease- Sclerodermoid Phase

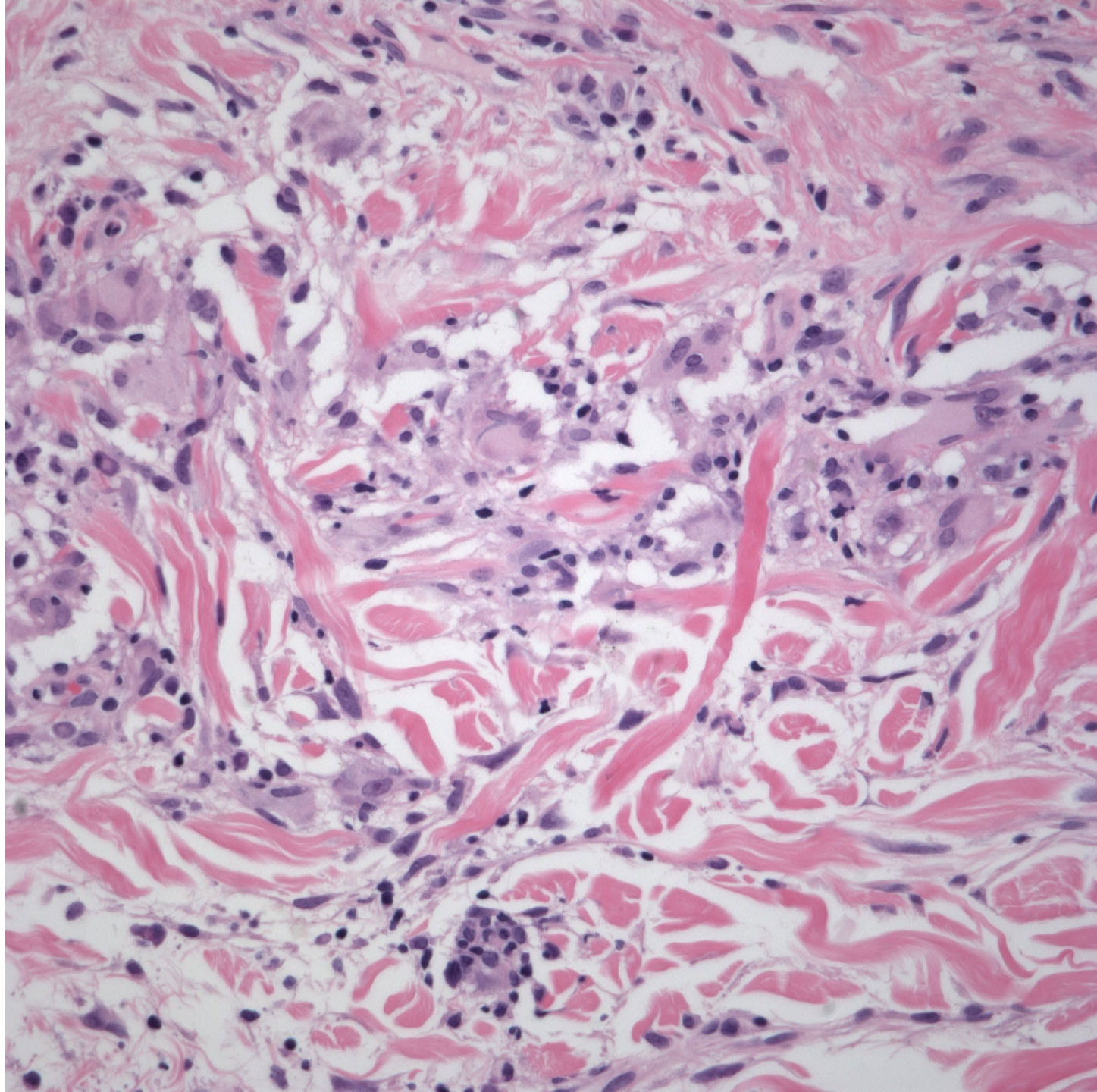


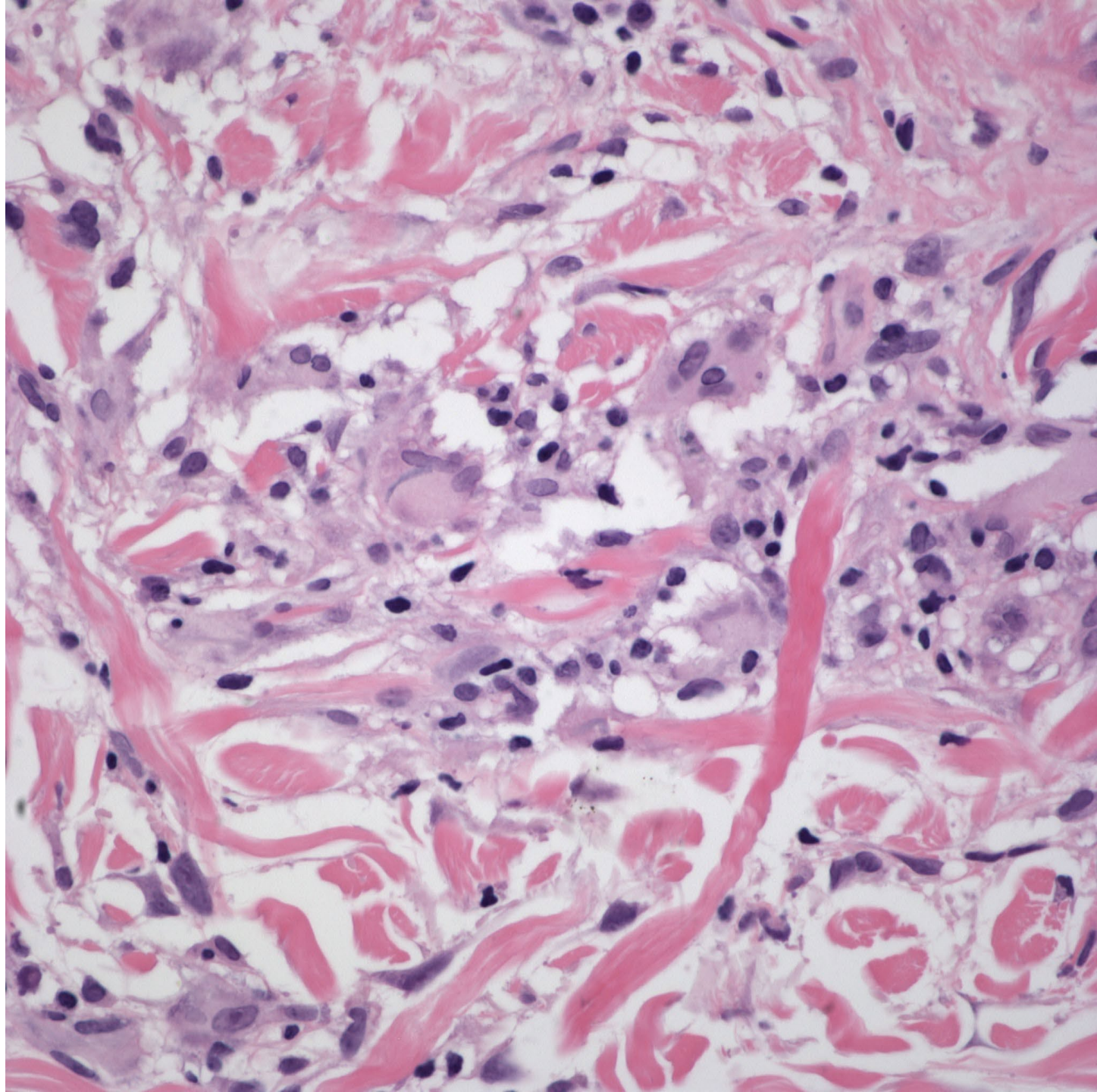
47 y.o. male with raised lesion
from left tricep





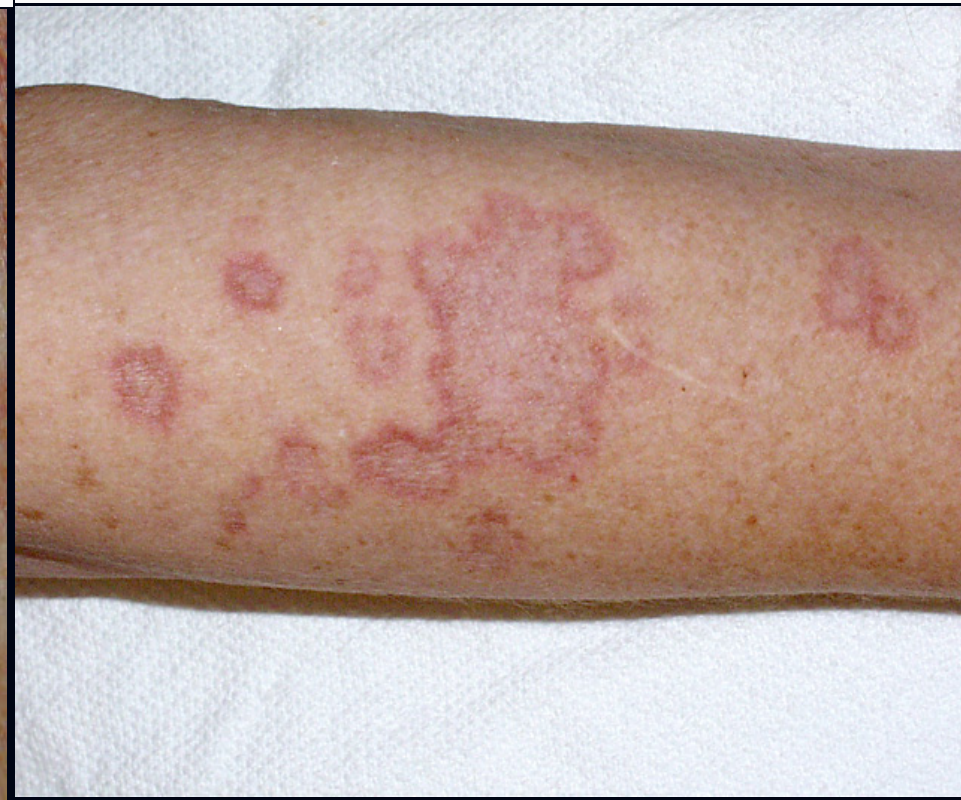
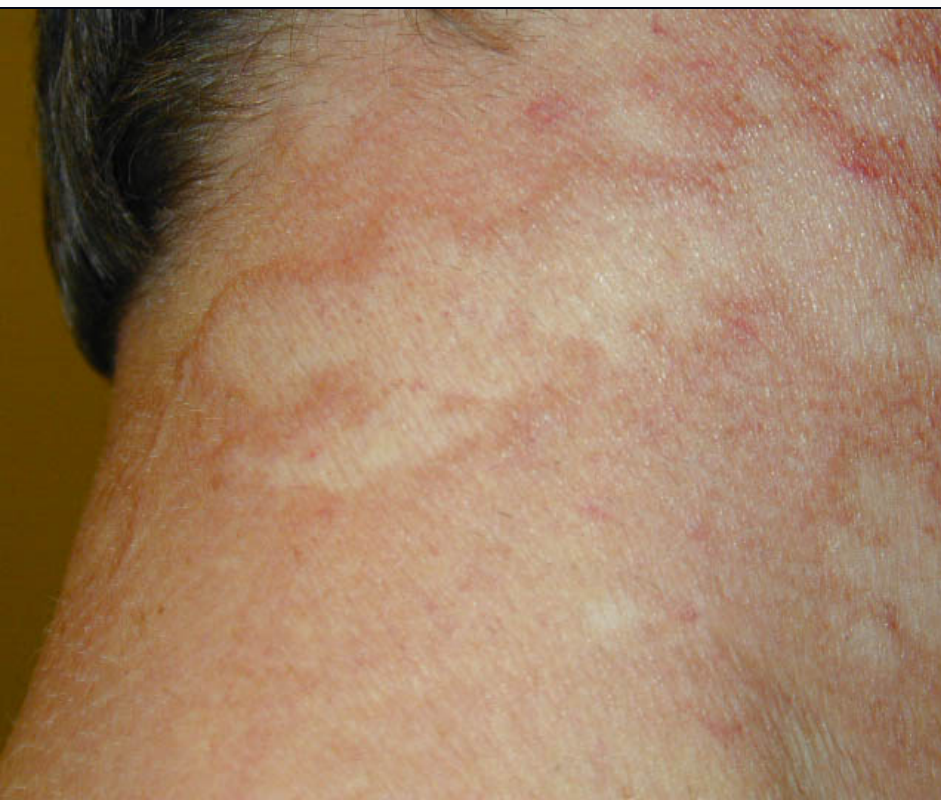
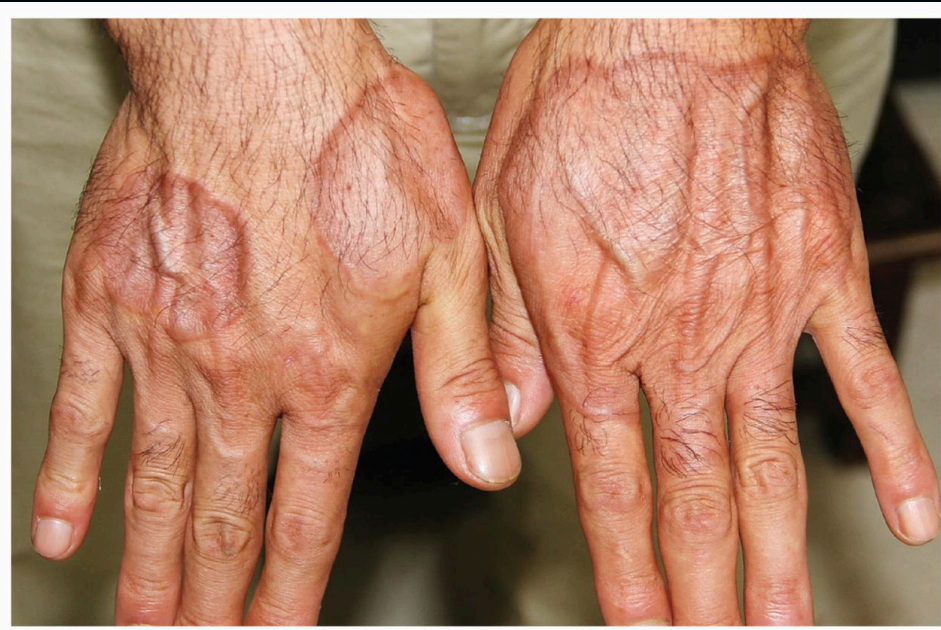
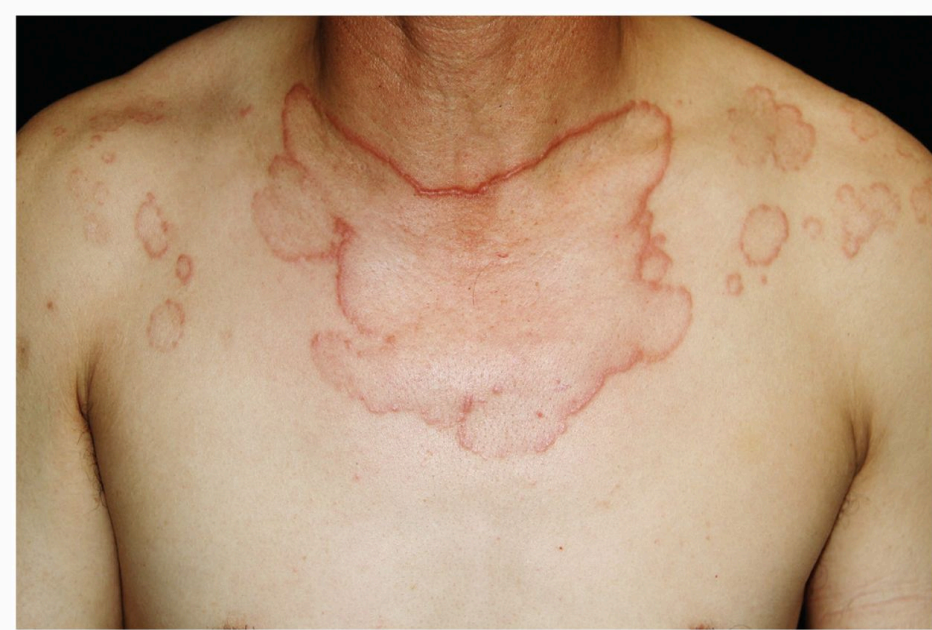
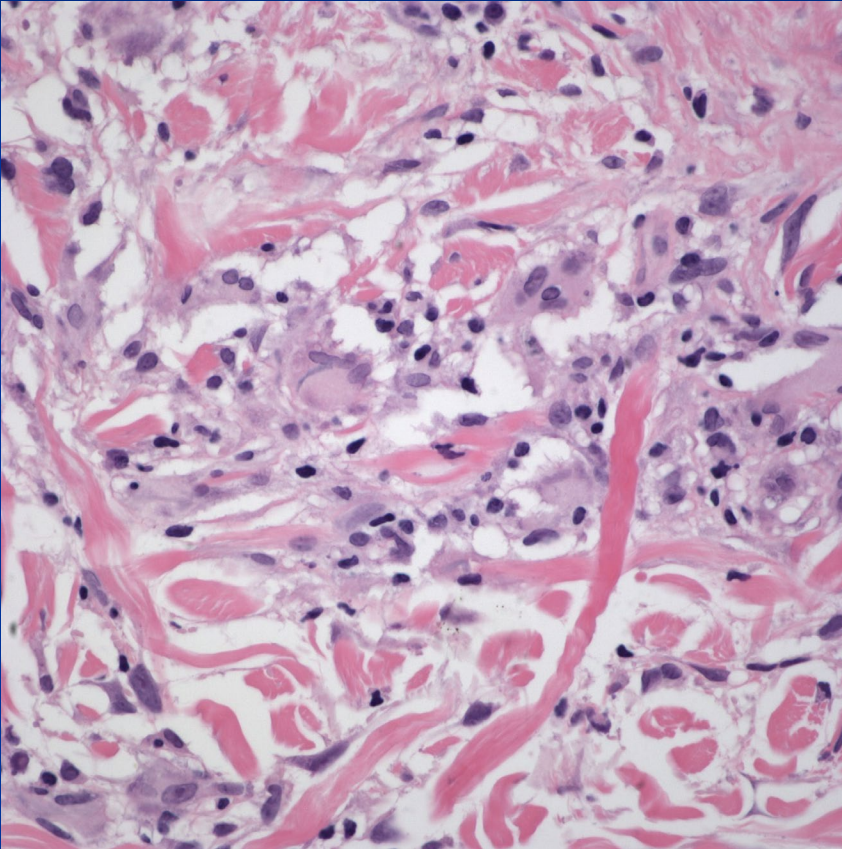


What is your differential diagnosis and what special stains/IHC would be helpful?

Annular Elastolytic Granuloma (Actinic Granuloma of O'Brien)

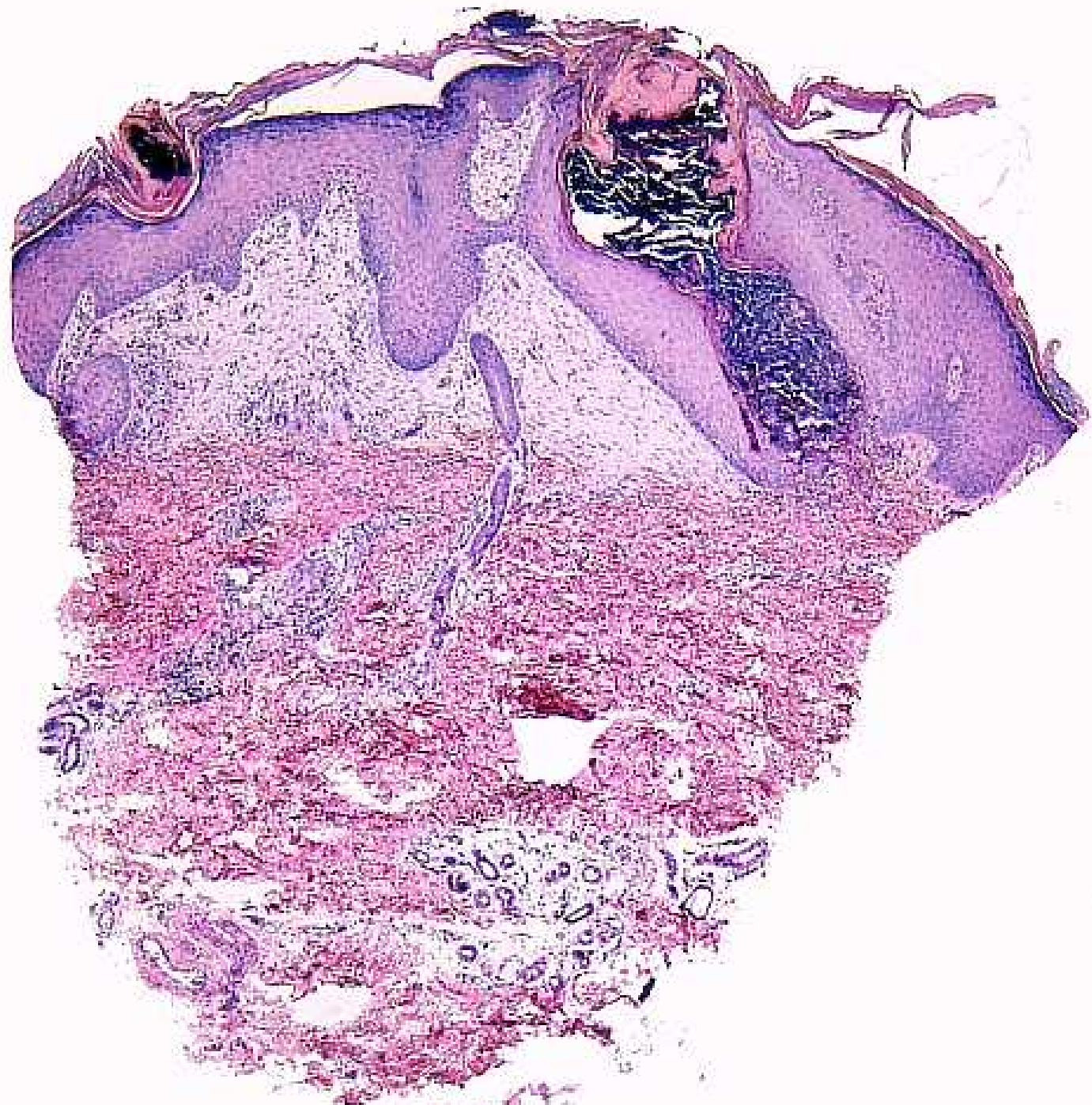


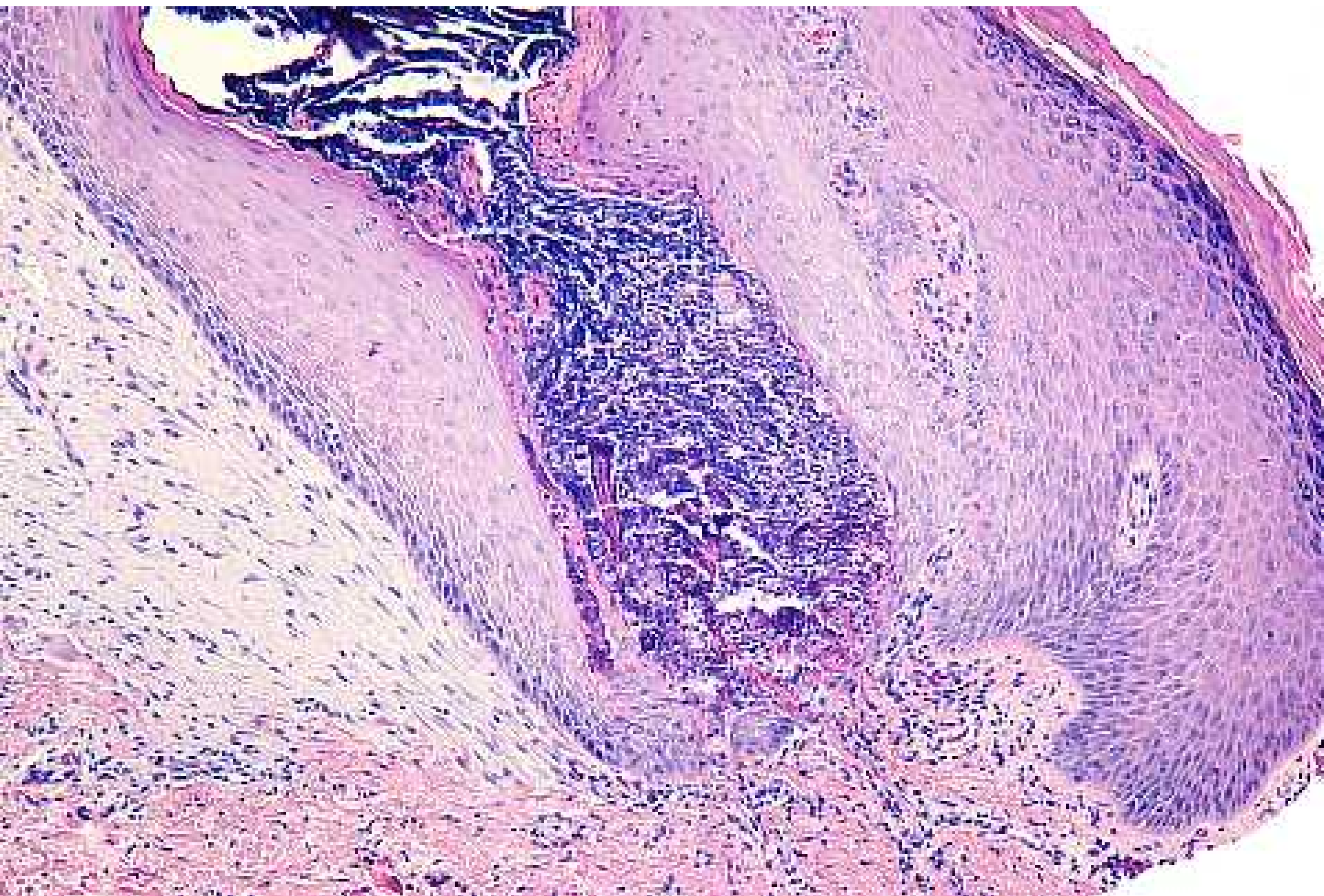
Histopathology

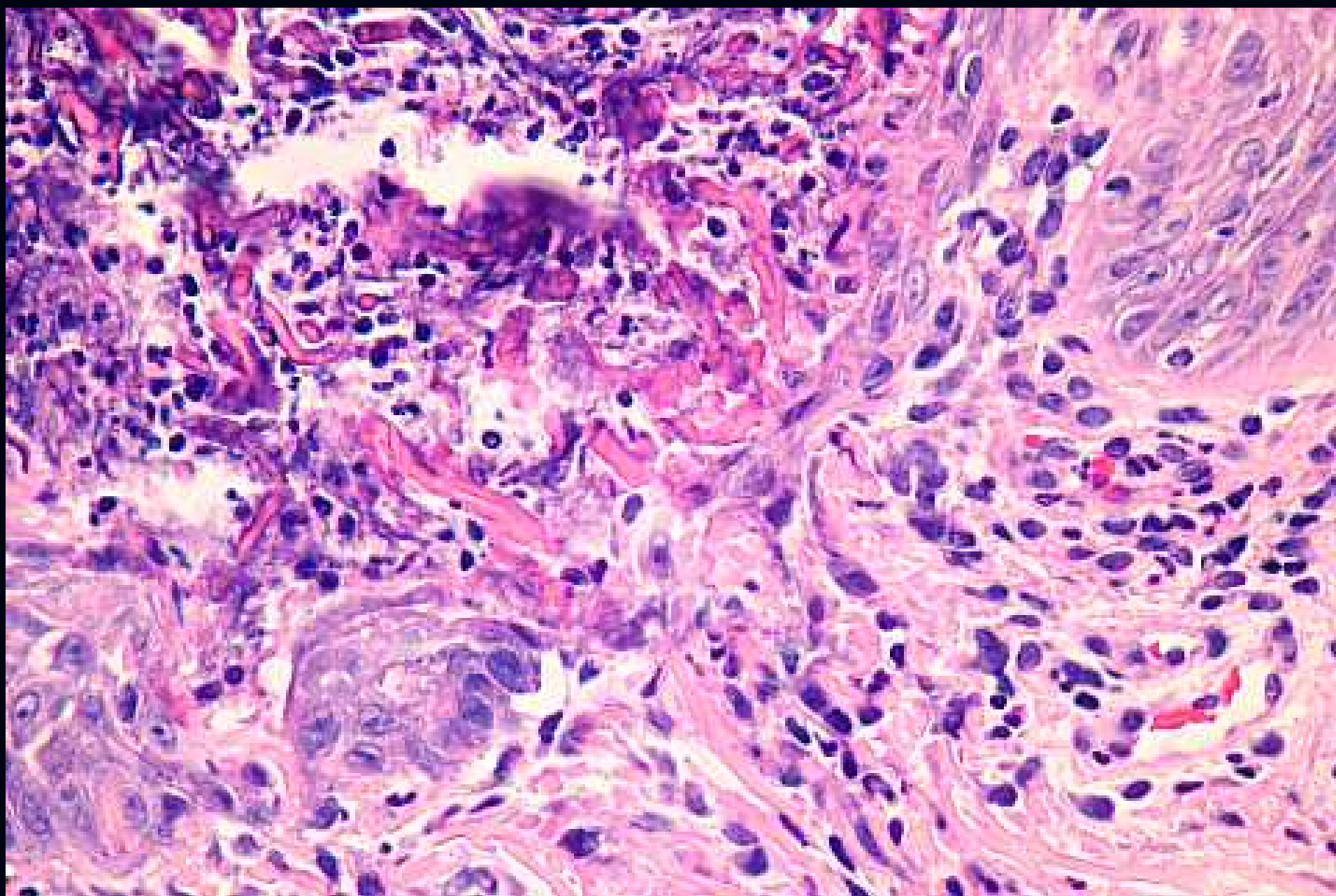


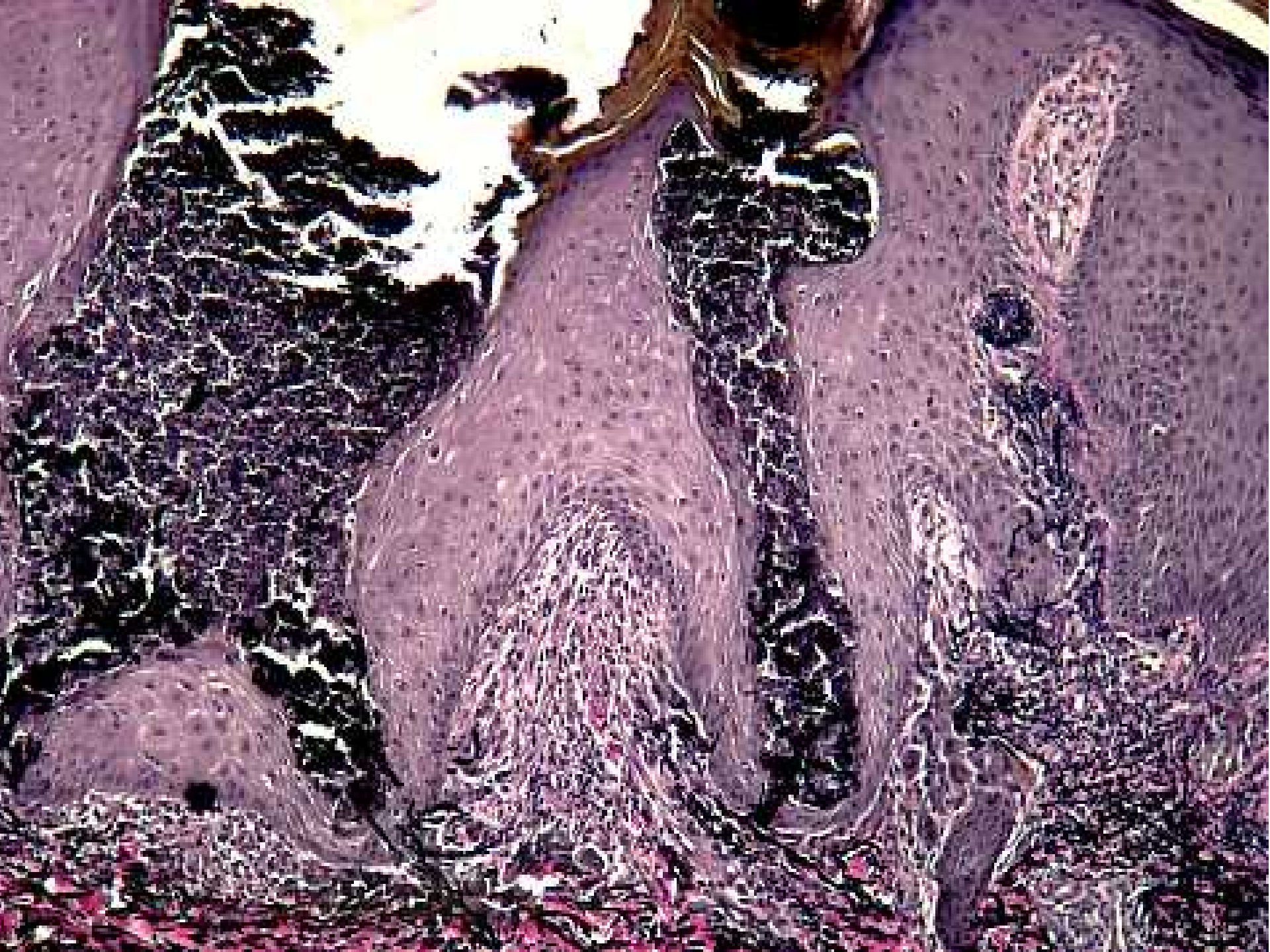
- May show retraction of overlying epidermis
- Palisading of giant cells and histiocytes on sun damaged skin
- Giant cells engulfing fragmented elastic fibers

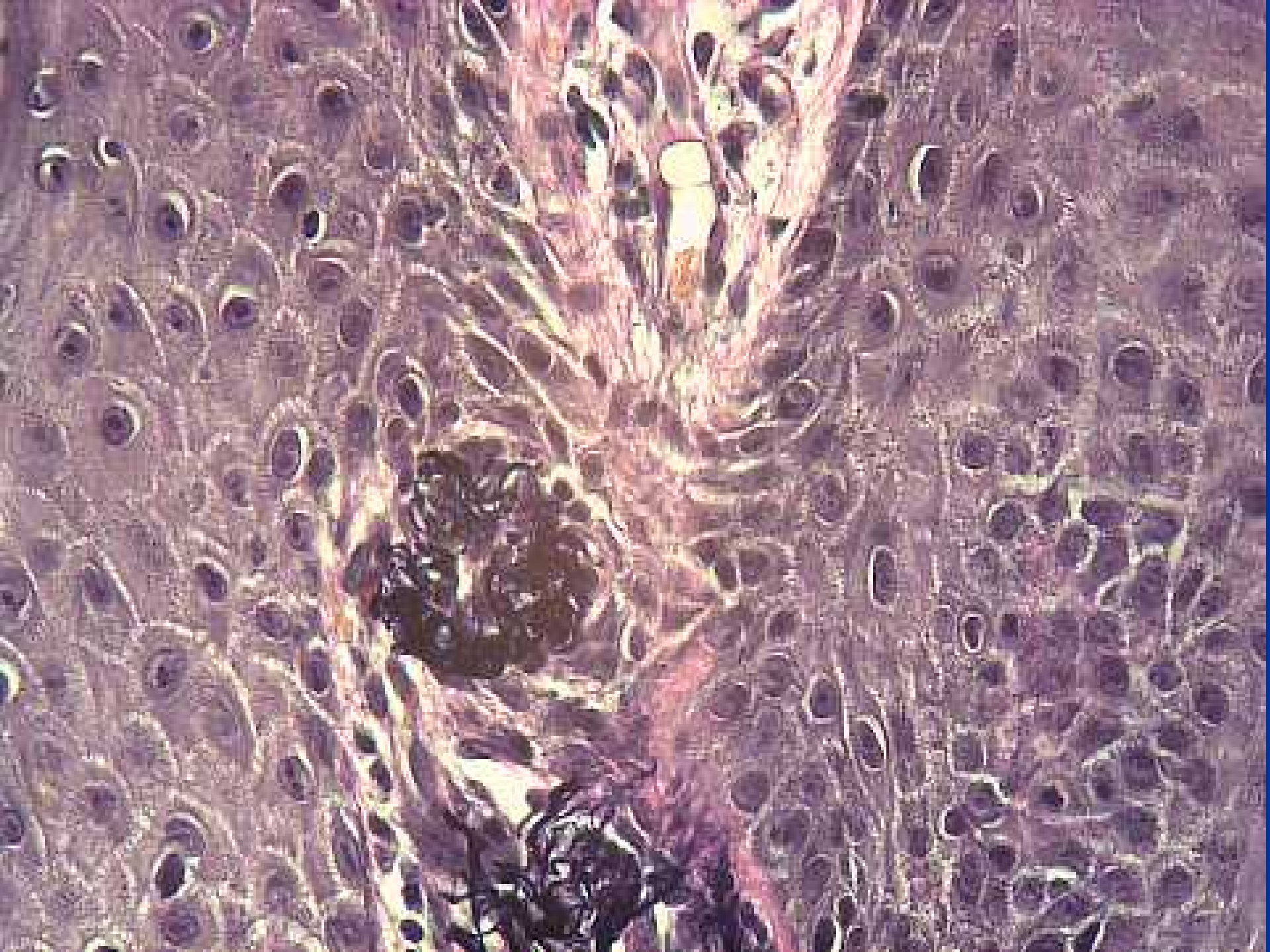
What are these diseases
associated with structural
changes in elastic fibers?



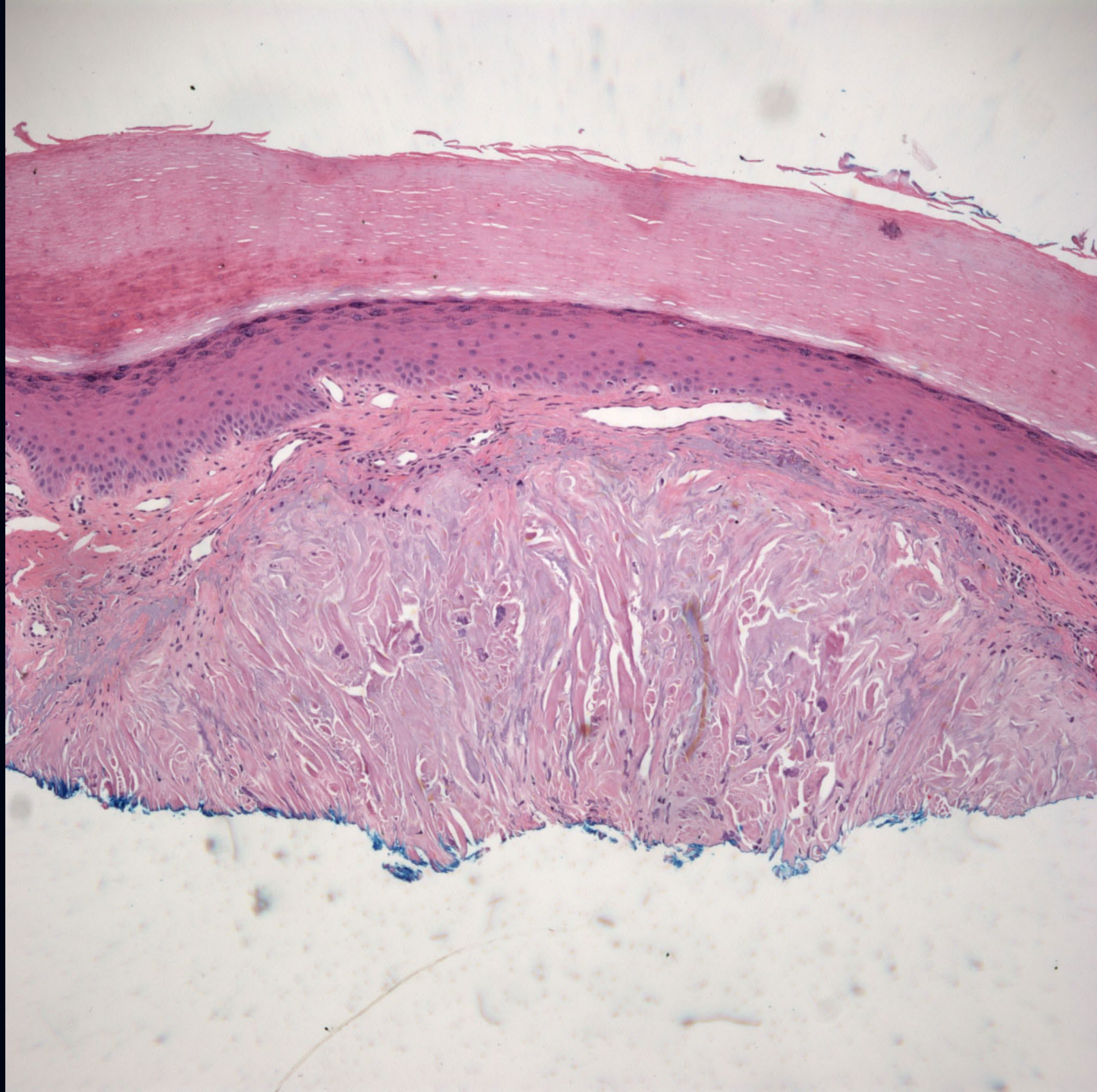


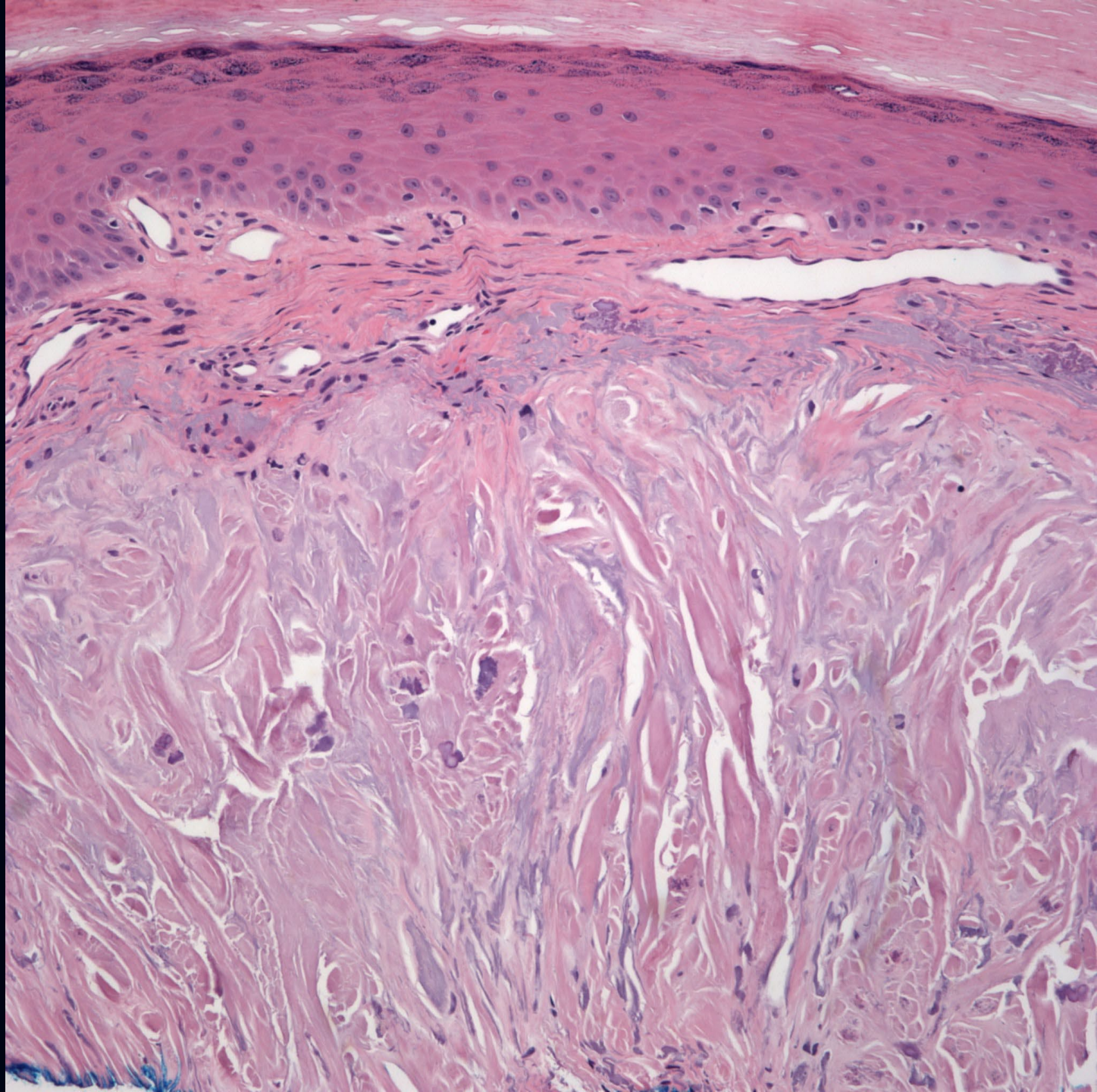


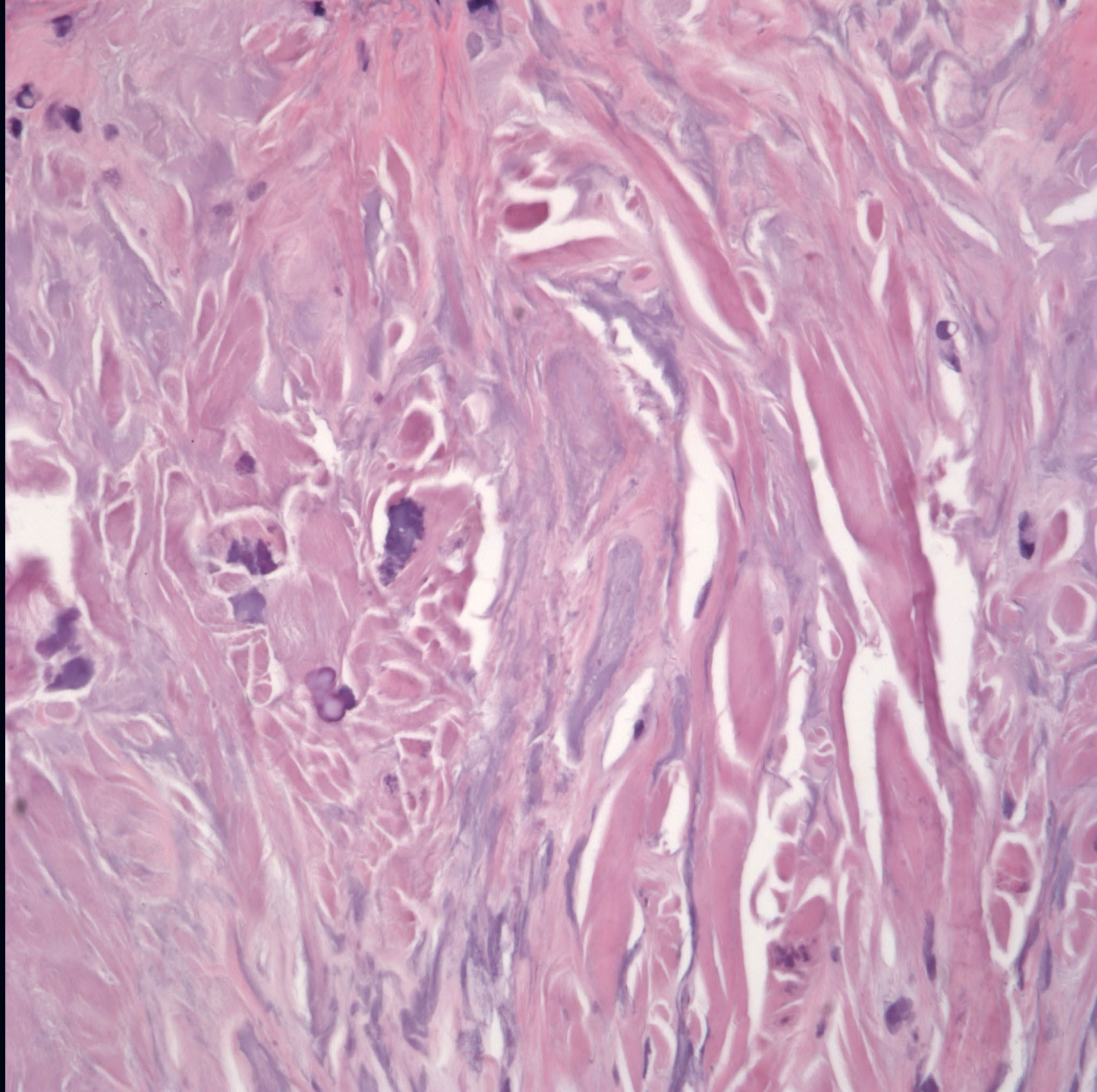


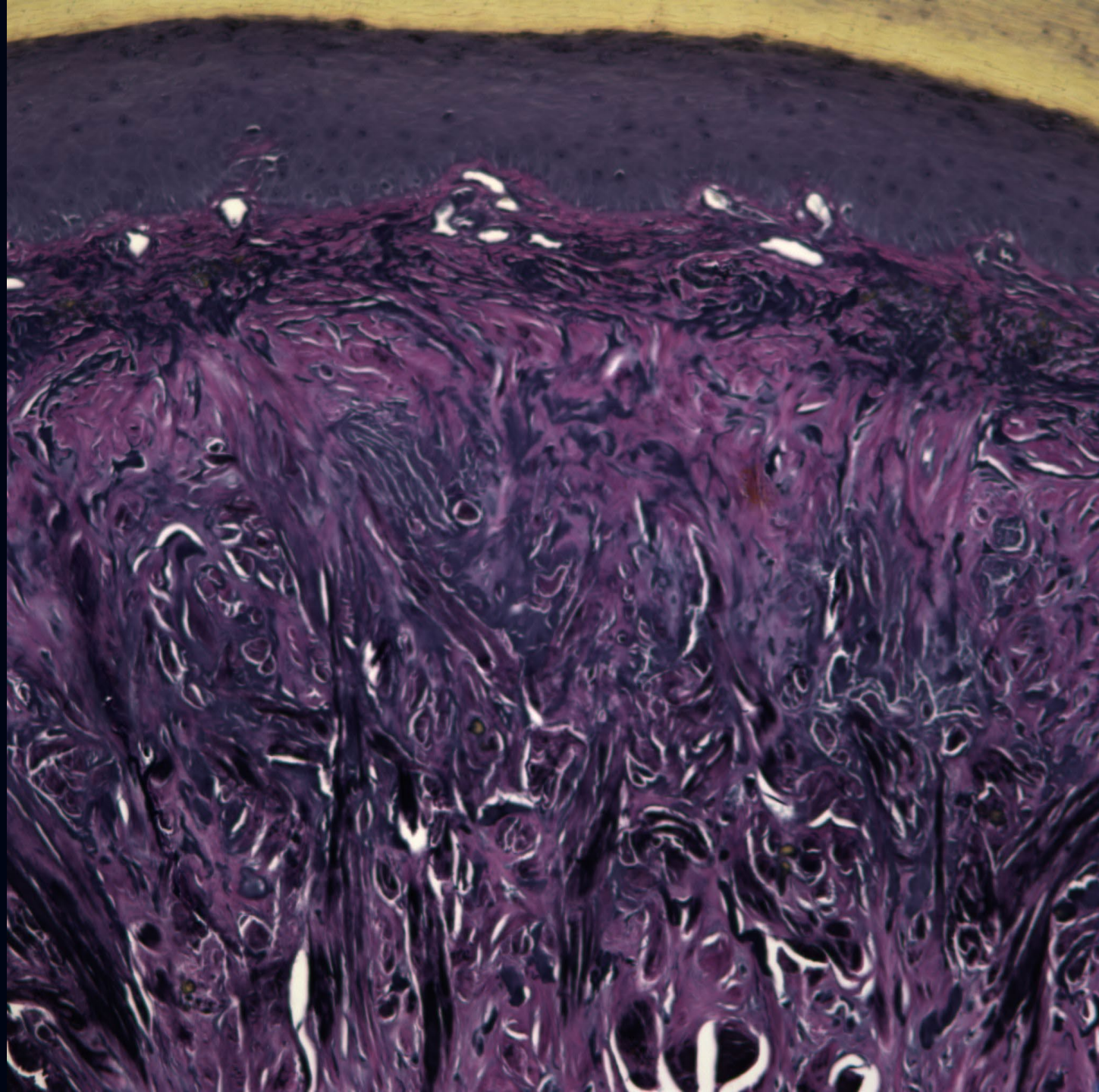


Elastosis Perforans Serpiginosa

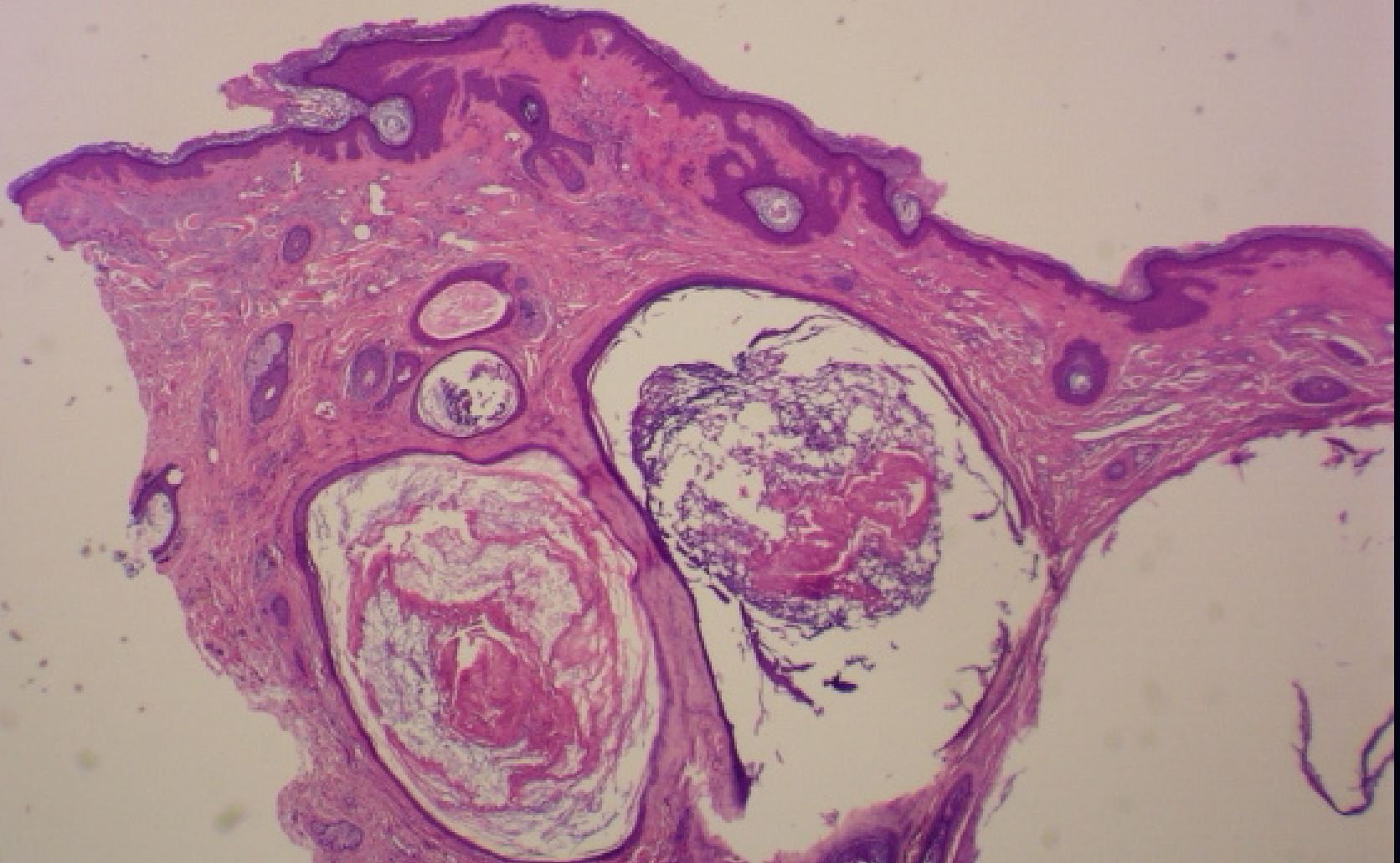


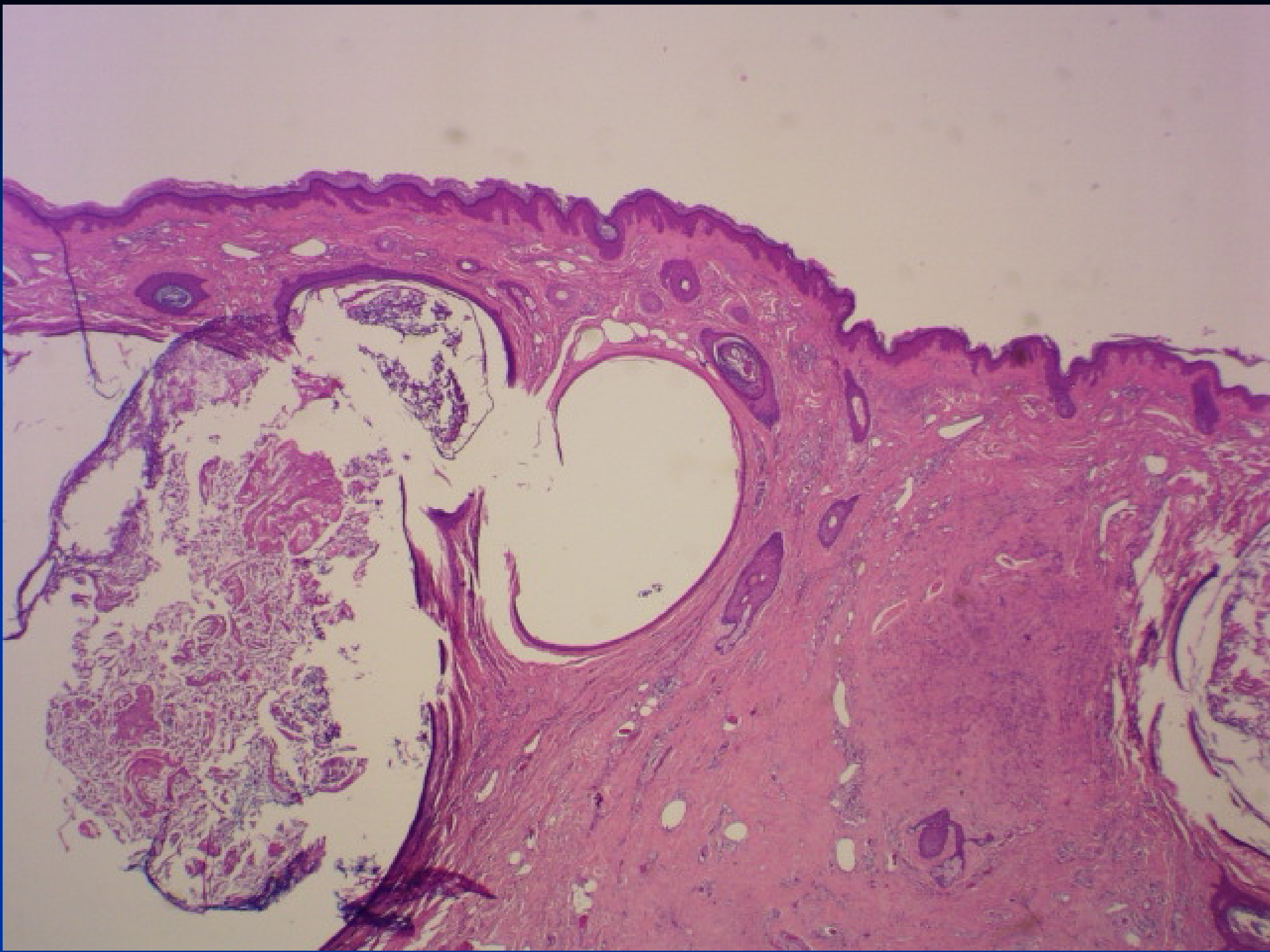


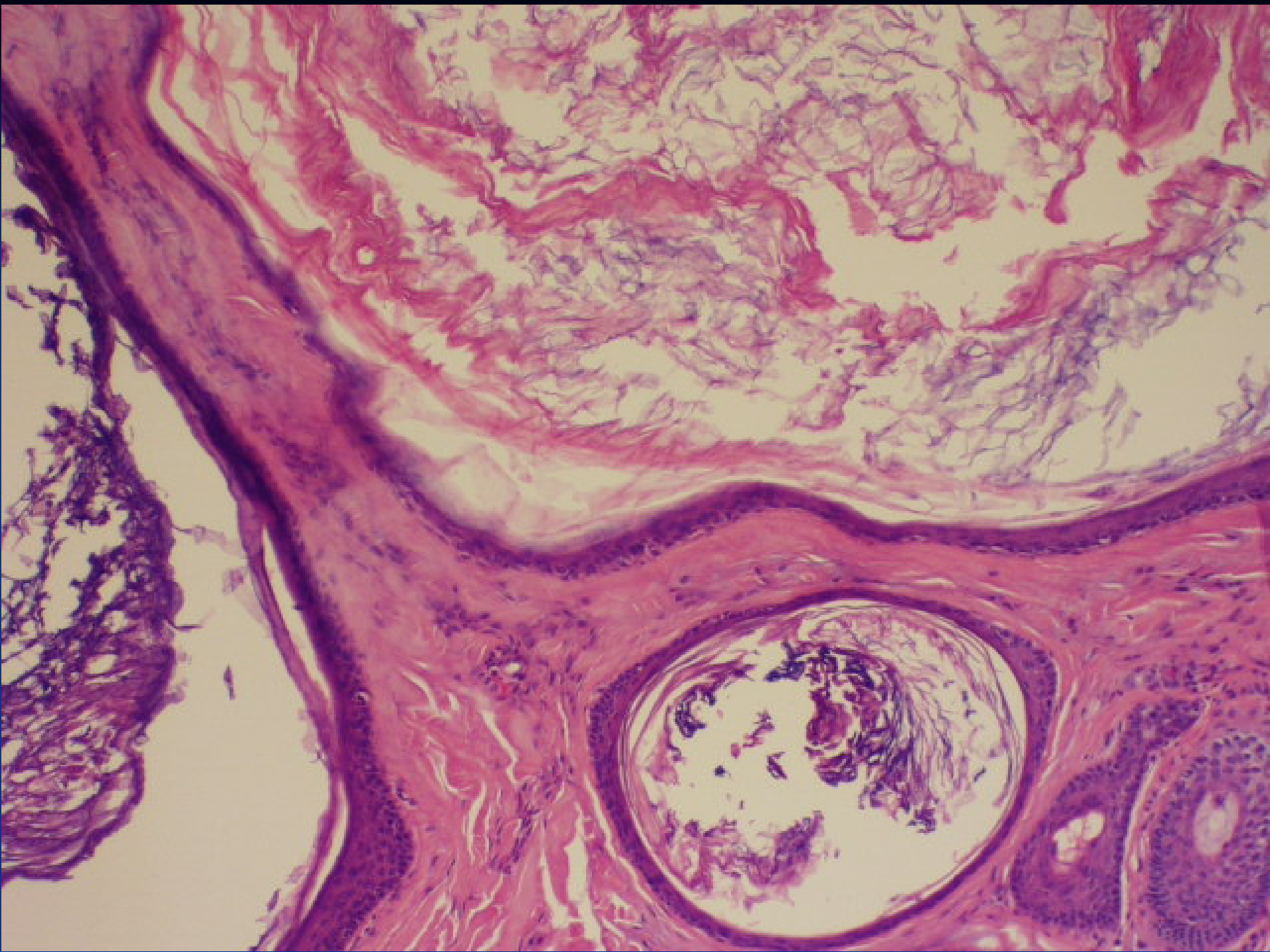


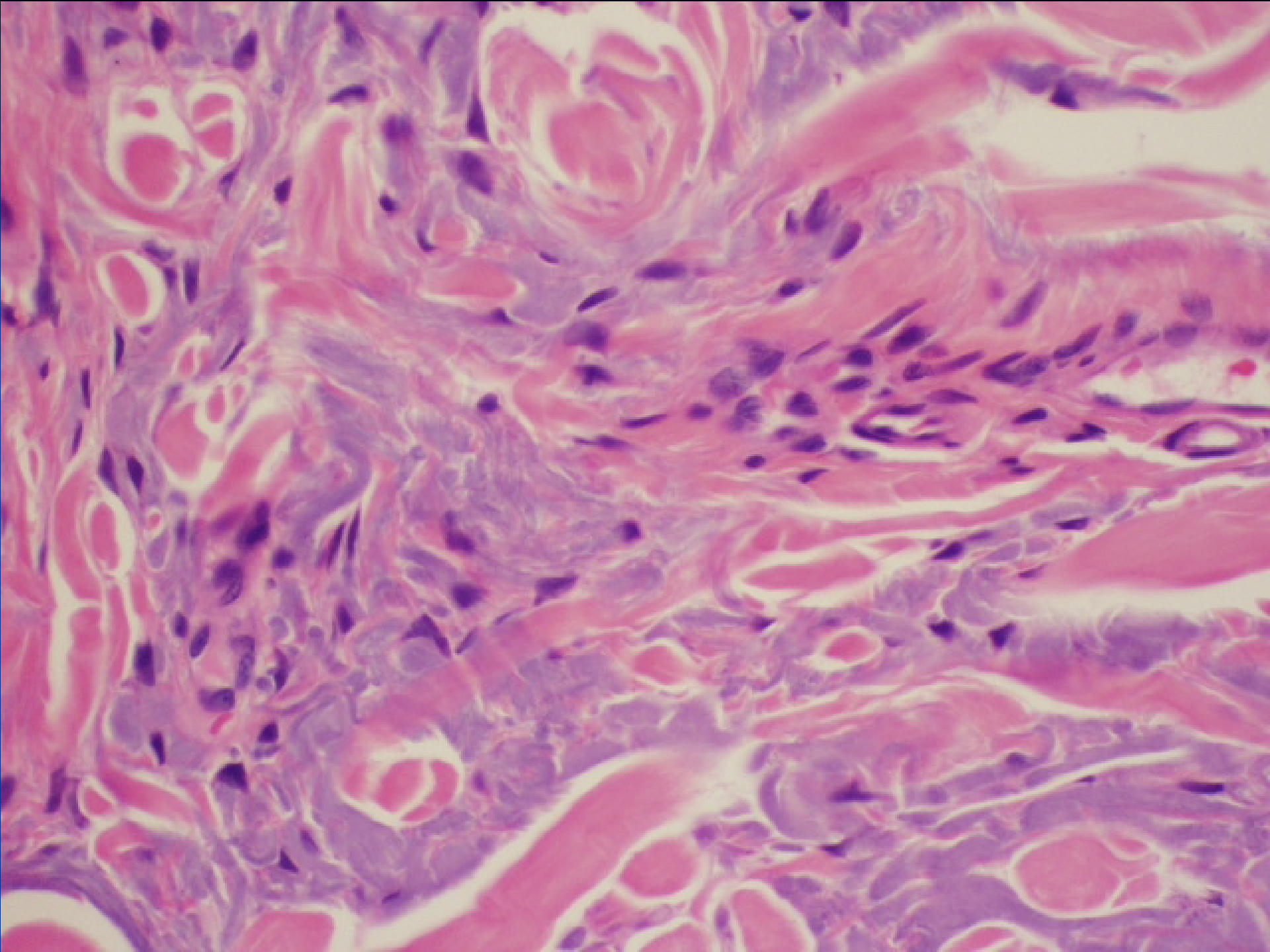


Degenerative Collagenous Plaques of the Hands









Favre-Racouchot Syndrome (Nodular Elastosis with Cysts and Comedones)

Dermatopathology Slide Review Part 9

Paul K. Shitabata, M.D.

Dermatopathology Institute